

Angiosome-Directed Therapy for the CLI Patient

Case studies and the literature show the benefits of direct and indirect flow revascularization.

BY JIHAD A. MUSTAPHA, MD; LARRY J. DIAZ-SANDOVAL, MD; AND FADI SAAB, MD

Historically, the initial treatment of choice for revascularization of patients with critical limb ischemia (CLI) was lower extremity bypass grafting with autologous vein.¹ With the publication of the randomized PREVENT III trial, it became apparent that real-world open revascularization for CLI patients carried 30-day rates of graft failure, perioperative mortality, and myocardial infarction of 5.2%, 2.7%, and 4.7%, respectively, as well as an overall primary graft patency rate of 61% at 1 year.² As endovascular techniques and technologies have evolved, the paradigm of lower extremity revascularization has shifted. The BASIL (Bypass Versus Angioplasty in Severe Ischemia of the Leg) trial was the first randomized study of patients with CLI and infrainguinal disease; however, it failed to show a significant difference in amputation-free survival (AFS) between revascularization modalities.³ With the advent of newer approaches, it has been found that octogenarian CLI patients and those with high operative risk, such as patients with advanced kidney failure or end-stage renal disease, benefit from revascularization and should therefore be considered for an endovascular-first approach.^{4,5}

ANGIOSOME-DIRECTED THERAPY

The concept of angiosome-directed therapy (ADT) has gained significant relevance. An angiosome is a three-dimensional anatomic unit of tissue (consisting of skin, subcutaneous tissue, fascia, muscle, and bone) fed by a source artery and drained by specific veins. The foot and ankle arterial angiosome is represented as a topographic map that is divided into six territories; each territory is fed by three main arteries and their branches. The posterior tibial (PT) artery feeds three angiosomes: the medial calcaneal, supplying the medial plantar aspect of the heel; the medial plantar, supplying the corresponding plantar surfaces; and the lateral plantar, also supplying the corresponding plantar surfaces. The peroneal artery (PA) feeds two angiosomes: the lateral calcaneal, supplying the lateral aspect of the heel, and the anterior communicating artery, supplying

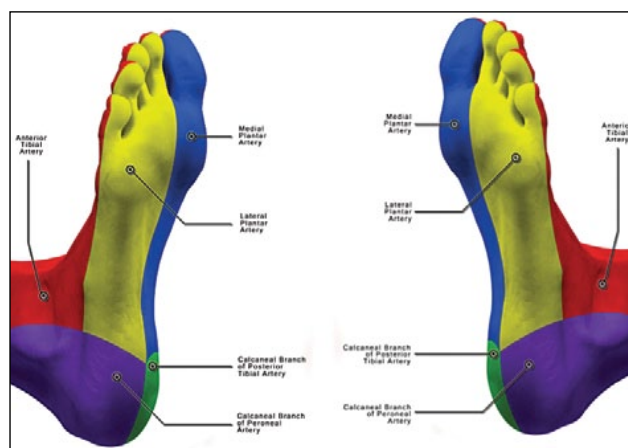


Figure 1. The foot and ankle arterial angiosome is represented as a topographic map divided into five territories, provided by three main arteries and their branches as shown in the right foot (A) and the left foot (B).

the anterior aspect of the ankle. The anterior tibial (AT) provides one angiosome—the dorsalis pedis (DP) angiosome, supplying the dorsum of the foot (Figure 1).

ADT refers to the establishment of flow to the topographic area of the foot where the wound is located. This can be achieved via direct flow, defined as inline, pulsatile flow through the affected angiosome source artery, or indirect flow, represented by the strategy whereby flow to the wound area is provided by collaterals fed by an arterial conduit that is revascularized, as no direct flow is considered feasible. When the indirect flow approach is utilized, the recommendation is to open as many vessels as possible to increase the volume of blood to the foot (volume concept). As new techniques are being developed and carried into practice—including ultrasound-guided tibiopedal access and interventions, transcollateral tibial interventions, and digital and transmetatarsal artery access and interventions—it appears that the future holds promise with regard to the ability to intervene in these complex patients.^{6,7}

ISCHEMIC ULCERS

Patients with CLI typically have disease involving multiple levels (ie, aortoiliac, femoropopliteal [FP], and infrapopliteal [IP]), but fewer than 10% have hemodynamically significant disease in all three levels.⁸⁻¹⁰

Approximately 33% of patients with infrainguinal disease (FP and IP) present with predominantly isolated IP disease, and the other 67% present with both FP and IP disease.^{3,11-13} Isolated IP disease is mainly seen in the elderly (age > 80 years), patients with diabetes, or dialysis-dependent patients.¹² These patients are at higher risk for amputation and shorter AFS time compared to those with FP and IP disease (median AFS, 17 months vs 37 months; $P = .001$).¹³ The improved prognosis of patients with combined FP and IP disease is likely related to the development of collateral systems that have been observed to mature in four major zones that are of paramount importance for ADT. The number and quality (diameter) of these collaterals is related in part to the degree of disease (high-grade stenosis vs chronic total occlusions [CTOs]). For the sake of this article, we will refer to these collateral systems as the Peripheral Registry of Endovascular Clinical Outcomes (PRIME) zones (Figures 2 and 3).

PRIME zone 1 collaterals originate primarily from the profunda and, to a lesser extent, from the proximal superficial femoral artery (SFA). PRIME zone 2 collaterals originate in the distal SFA and the P1–P2 segments of the popliteal artery, depending on the occlusive state. PRIME zone 3 collaterals originate from the P3 segment of the popliteal and proximal tibial arteries, including the tibioperoneal trunk. PRIME zone 4 collaterals originate from the distal tibial arteries, primarily from the PA and, to a lesser extent, from the AT and PT arteries.

Having determined the type of flow needed for an ischemic foot, the next step is to visualize the interrupted infrainguinal arterial flow. When observing an arterial occlusion during angiography, it is important to remain on cine long enough to visualize the collateral vessels, which serve to show the interventionist the points of reconstitution of the multilevel CTOs, so that a reconstruction strategy can be planned. Multilevel arterial occlusion requires either single-level revascularization to provide indirect flow to the ischemic foot (Figure 4) or multilevel revascularization to provide direct flow to the ischemic foot (Figure 5).

Direct flow revascularization is straightforward. The goal is to re-establish arterial patency in line to the ischemic area. If revascularization is more complex, it requires basic knowledge of the different levels of collaterals, as previously described. In patients with CLI, collaterals at PRIME zones 3 and 4 are crucial for indirect revascularization. Knowing how they function allows the operators to choose an arterial flow restoration plan to achieve the best indirect brisk flow possible.

There have been different approaches studied with regard

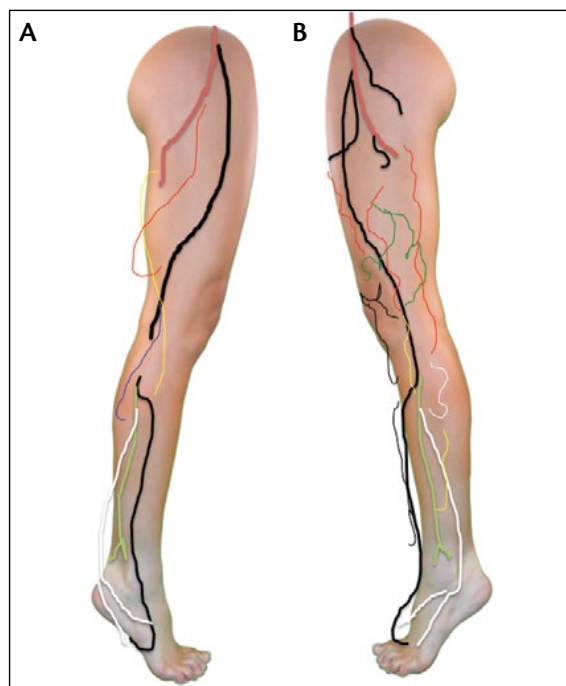

Figure 2. The value of collaterals in CLI patients. Collaterals consistent with high-grade stenosis (A). Collaterals more common in CTOs (B).

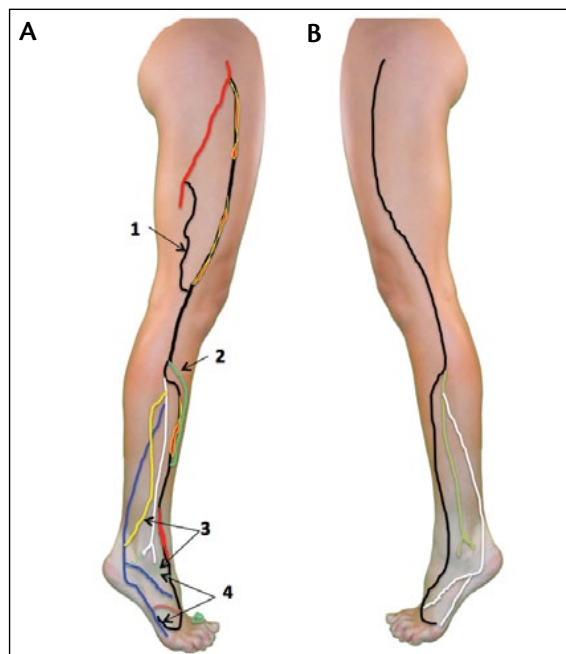


Figure 3. Multiple-level CTOs, typical in CLI patients (A). Also shown are the four PRIME collateral zones that keep the limbs intact while metabolic supply and demand are balanced (stable state): (1) the collateral path from the profunda to the popliteal and genicular branches; (2) the collateral path from the popliteal and genicular branches to the tibial arteries; (3) the collateral path from the proximal tibials to the distal tibials; (4) the pedal loop's collateral paths. Normal, expected, infrainguinal runoff (B).

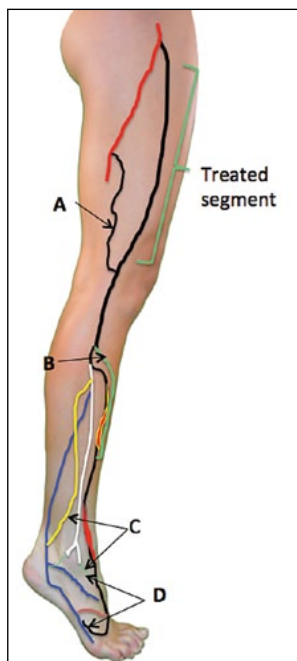


Figure 4. Multilevel arterial occlusion. Treated segment of the SFA and popliteal leads to indirect blood flow to the ischemic foot via collaterals from PRIME zones 3 and 4 after direct flow has been established to the level of the infrapopliteal CTO.

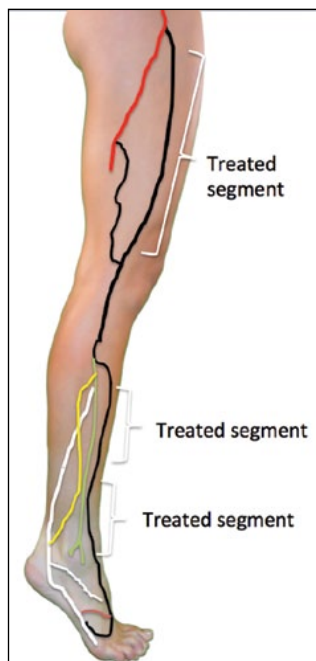


Figure 5. Imaging after complete revascularization of the popliteal and the tibials, leading to direct flow to the ischemic foot.

to ADT, and the results are controversial. Attinger et al showed a 9% healing failure rate when wounds were

treated using the angiosome concept to achieve direct flow compared to a 38% failure rate when revascularization was achieved via indirect flow.¹⁴ In this study, limb salvage rates (LSR) were also superior when direct flow was achieved. Iida et al studied 203 CLI limbs, achieving LSR of 86% with direct flow versus 69% with indirect flow,¹⁵ with results originally confirmed by Varela et al.¹⁶ However, in a more recent study, Acín and Varela's group found that among diabetic patients with CLI, a direct flow versus an indirect flow strategy did not influence outcomes, nor did the number of revascularized tibial vessels.¹⁷ This stands in contraposition to Lejay et al, who found that among diabetic patients with CLI undergoing open revascularization, LSR were superior when direct flow was achieved following ADT.¹⁸

Only one prospective study has been published comparing the strategies of direct flow and indirect flow to the ischemic angiosome. In 64 CLI patients with single-vessel runoff to the foot, direct flow was achieved in 61%. Ulcer healing at 1, 3, and 6 months was superior with direct flow than with indirect flow. However, there was no statistically significant difference in LSR.¹⁹

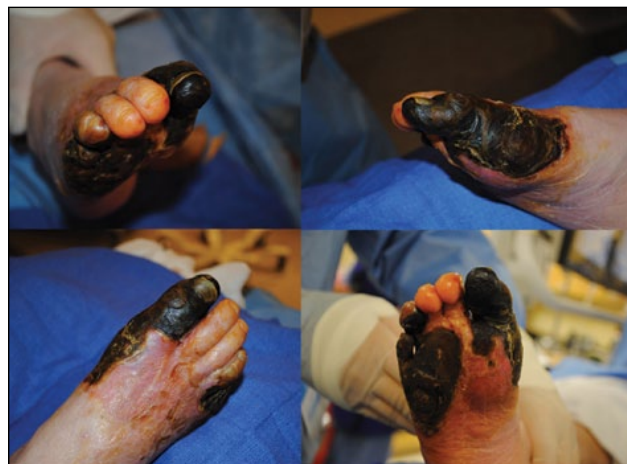

Figure 6. These four images show the geographic distribution of the missing tibial pedal arteries and provide a hint of what is possibly still patent.

One of the most significant hurdles in the real world is that direct flow to the ischemic angiosome may not be attainable in a large number of CLI patients. Berceli et al reported on the efficacy of DP bypass for ischemic forefoot and heel ulcerations.²⁰ According to the angiosome concept and this strategy, the forefoot would receive direct flow, whereas the heel would be perfused via indirect flow. The LSR of 86% indicated that heel ulcerations can heal with indirect flow, even in the absence of an intact pedal arch, presumably through interangiosome connections for perfusion.

ANGIOSOME EVALUATION

It is not always possible to provide direct flow for all the cutaneous angiosomes, and operators have to use the indirect flow revascularization strategy to achieve maximum pedal reconstruction. A patient presented with distal forefoot gangrene changes that evolved over 4 weeks (Figure 6). The cutaneous angiosome in these pictures of the foot are consistent with arterial disease

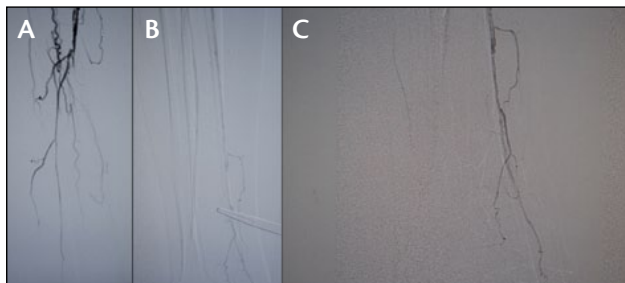


Figure 7. Arterial angiosome mapping. SFA/popliteal CTO without clear collateral-aided reconstitution of the distal popliteal or proximal tibial arteries (A). Tibial runoff not showing intact arterial flow (B). Faint dorsalis pedis flow and absent rest of the pedal circulation (C).

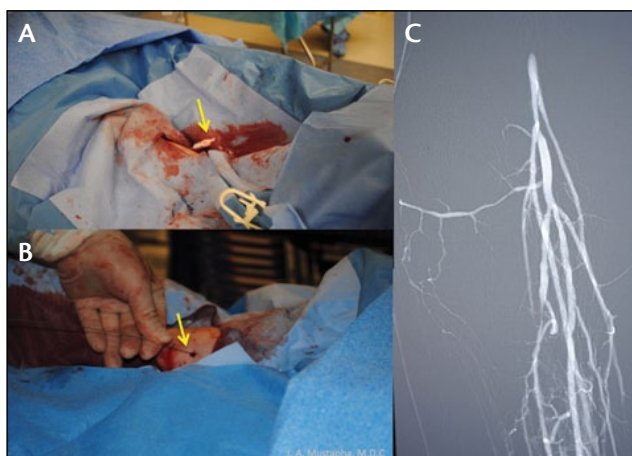


Figure 8. ADT for tibial access. Tibial sheath (B; arrow). Retrograde CTO crossing wire (B; arrow). Initial retrograde arterial tibial angiogram (C).

involving the anterior and posterior circulations of the foot. This type of data lead operators to further evaluate the arterial circulation.

Cutaneous angiosome evaluation is a unique first step during the evaluation process of the CLI patient with ischemic tissue breakdown. The four images in Figure 6 show the geographic distribution of the missing tibial pedal arteries and gives a hint as to which vessels are possibly still patent.

Because CLI is a multilevel, multivessel disease, the next step for this patient was an arterial angiosome evaluation. The initial angiogram showed severe arterial disease with a CTO of the SFA and no sufficient tibial pedal runoff (Figure 7). The lack of arterial flow in the popliteal and tibial pedal circulation makes it difficult to decide a therapeutic option, as there is no visible target conduit to revascularize into. Again, based on the cutaneous angiosome, the operators proceeded to find the anterior and posterior circulation to restore blood supply to the ischemic tissue. An antegrade angiogram was insufficient. A retrograde selective diagnostic angiogram was obtained, which uncovered valuable hibernating arterial conduits (Figure 8). The treatment plan was initiated based on the angiosomes evaluated. Both antegrade and retrograde accesses were achieved. The retrograde access was achieved in an attempt to provide ADT. Revascularization was successful in the SFA/popliteal, along with the PA and PT arteries (Figure 9). Based on the cutaneous pedal angiosome, the AT was needed for complete direct revascularization. An attempt to open the AT was unsuccessful, leaving this patient with indirect angiosome therapy.

In this type of scenario, operators must evaluate the type of flow that the foot is receiving. A few important

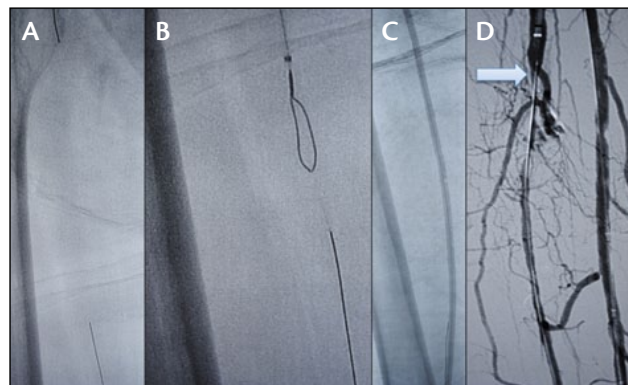


Figure 9. Antegrade and retrograde CTO crossing wires and devices (A). Antegrade snare and retrograde wire (B). Percutaneous transluminal angioplasty (C). Antegrade angiogram of the tibial arteries (D), with arrow showing the tibio-peroneal CTO site.

features when using the indirect flow ADT strategy are brisk flow to the foot via the indirect tibial artery, an intact pedal loop, retrograde flow into the occluded tibial artery via the pedal loop, and contrast blush grade 3 of the ischemic tissue. These features are signs that the ischemic tissue is able to receive enough supply of oxygen and nutrients to meet the increased metabolic demand, restoring the metabolic balance and increasing the likelihood of healing (Figure 10). Figure 10C shows pedal revascularization, including the DP and AT. This is consistent with indirect flow via pedal loop retrograde filling into the target tibial artery, which did not receive antegrade direct flow. A final angiogram showed direct flow in all the vessels above the knee, but below the knee, there was direct flow into the PT and PA arteries and indirect flow into the AT (Figure 11). To confirm successful revascularization, these patients should be followed closely in the wound clinic until the ischemic tissue is healed and the skin is intact (Figure 12).

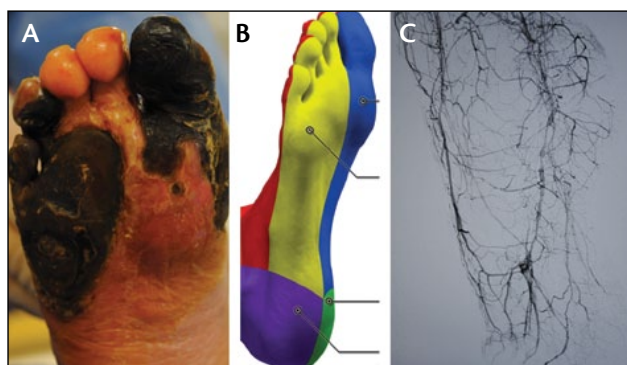


Figure 10. Cutaneous angiosome of the right foot (A). Cutaneous angiosome model (B). Arterial angiogram of the pedal circulation (C).

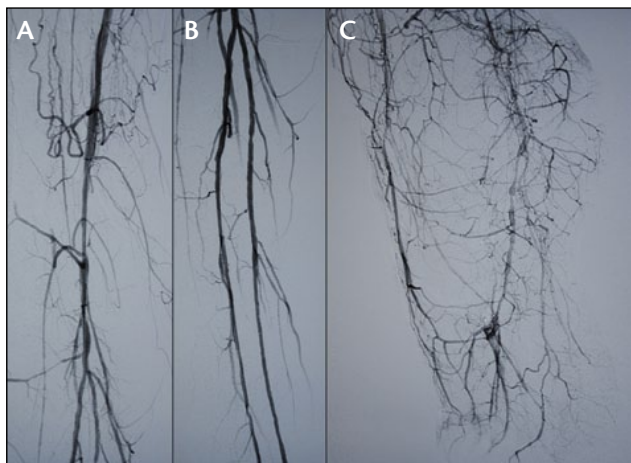


Figure 11. Imaging after revascularization of the SFA into the popliteal (A). Restored flow into the tibial arteries (B). Pedal revascularization, including the dorsalis pedis and AT artery (C). This is consistent with pedal loop retrograde flow into the target tibial artery, which did not receive direct antegrade flow.

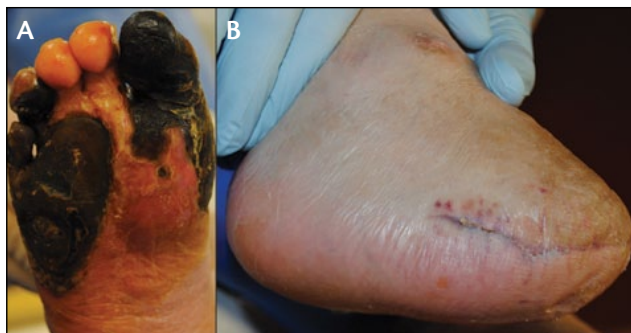

Figure 12. Right foot before revascularization and transmetatarsal amputation (A). Final results (B).

CONCLUSION

The results from published studies looking at the best reperfusion strategy to treat CLI are contradictory. Some favor the angiosome concept, and others favor the volume concept. Unfortunately, these are retrospective studies, most of which represent single-center efforts and are therefore strongly tied to the experience of the operators. Before generalizable recommendations can be designed on an evidence-based foundation, further data of better quality are needed.

In the meantime, the authors can make two recommendations. When treating CLI patients with below-the-knee lesions, attempts to obtain direct inline and pulsatile flow to the wound should be undertaken. In cases in which this is not possible, every effort should be made to restore as much blood flow as possible to the foot. For these patients, attempts at restoration of the pedal loop and arch reconstruction should be carried out as far as technically feasible to obtain blush flow to the ischemic

tissue and retrograde flow to the missing vessel. CLI patients benefit from both direct and indirect angiosome-based therapies. ■

Jihad A. Mustapha, MD, is the Director of Cardiovascular Catheterization Laboratories, Metro Health Hospital, Wyoming, Michigan; and Clinical Assistant Professor of Medicine, Michigan State University CHM and COM, East Lansing, Michigan. He has disclosed that he has no financial interests related to this article. Dr. Mustapha may be reached at jihad.mustapha@metrogr.org.

Larry J. Diaz-Sandoval, MD, is an interventional cardiologist with Metro Health Hospital, Wyoming, Michigan; and Clinical Assistant Professor of Medicine, Michigan State University CHM and COM, East Lansing, Michigan. He has disclosed that he has no financial interests related to this article.

Fadi Saab, MD, is an interventional cardiologist with Metro Health Hospital, Wyoming, Michigan; and Clinical Assistant Professor of Medicine, Michigan State University CHM and COM, East Lansing, Michigan. He has disclosed that he has no financial interests related to this article.

1. Kudo T, Chandra FA, Kwun WH, et al. Changing pattern of surgical revascularization for critical limb ischemia over 12 years: endovascular vs. open bypass surgery. *J Vasc Surg.* 2006;44:304-313.
2. Conte MS, Bandyk DF, Clowes AW, et al. Results of PREVENT III: a multicenter, randomized trial of edifoligide for the prevention of vein graft failure in lower extremity bypass surgery. *J Vasc Surg.* 2006;43:742-751.
3. Adam DJ, Beard JD, Cleveland T, et al. Bypass vs angioplasty in severe ischaemia of the leg (BASIL): multicentre, randomised controlled trial. *Lancet.* 2005;366:1925-1934.
4. Ortmann J, Gahl B, Diehm N, et al. Survival benefits of revascularization in patients with critical limb ischemia and renal insufficiency. *J Vasc Surg.* 2012;56:737-745.
5. Brosi P, Dick F, Do DD, et al. Revascularization for chronic critical lower limb ischemia in octogenarians is worthwhile. *J Vasc Surg.* 2007;46:1198-1207.
6. Mustapha J, Saab F, McGoff T, et al. Tibio-pedal arterial minimally invasive retrograde revascularization in patients with advanced peripheral vascular disease: the TAMI technique, original case series. *Catheter Cardiovasc Interv.* 2014;83:987-994.
7. Palena LM, Brocco E, Manzi M. The clinical utility of below-the-ankle using "transmetatarsal artery access" in complex cases of CLI. *Catheter Cardiovasc Interv.* 2014;83:123-129.
8. European Working Group on Critical Limb Ischaemia. Second European consensus document on chronic critical leg ischaemia. *Eur J Vasc Surg.* 1992;6:1-32.
9. Wolfe JH, Wyatt MG. Critical and subcritical ischaemia. *Eur J Vasc Endovasc Surg.* 1997;13:578-582.
10. Aboyans V, Desormais I, Lacroix P, et al. The general prognosis of patients with peripheral arterial disease differs according to the disease localization. *JACC.* 2010;55:898-903.
11. Graziani L, Silvestro A, Bertone, et al. Vascular involvement in diabetic subjects with ischemic foot ulcer: a new morphologic categorization of disease severity. *Eur J Vasc Endovasc Surg.* 2007;33:453-460.
12. Gray BH, Grant AA, Kalbaugh CA, et al. The impact of isolated tibial disease on outcomes in the critical limb ischemic population. *Ann Vasc Surg.* 2010;24:349-359.
13. Sadek M, Ellozy SH, Turnbull IC, et al. Improved outcomes are associated with multilevel endovascular intervention involving the tibial vessels compared with isolated tibial intervention. *J Vasc Surg.* 2009;49:638-644.
14. Attinger CE, Evans KK, Mesbahi A. Angiosomes of the foot and angiosome-dependent healing. In: Sidawy AN, ed. *Diabetic Foot, Lower Extremity Disease and Limb Salvage*. Philadelphia, PA: Lippincott Williams & Wilkins; 2006:341-350.
15. Iida O, Nanto S, Uematsu M, et al. Importance of the angiosome concept for endovascular therapy in patients with critical limb ischemia. *Catheter Cardiovasc Interv.* 2010;75:830-836.
16. Varela C, Acin F, de Haro J, et al. The role of foot collateral vessels on ulcer healing and limb salvage after successful endovascular and surgical distal procedures according to an angiosome model. *Vasc Endovasc Surg.* 2010;44:654-660.
17. Acin F, Varela C, López de Maturana I, et al. Results of infrapopliteal endovascular procedures performed in diabetic patients with critical limb ischemia and tissue loss from the perspective of an angiosome-oriented revascularization strategy. *Int J Vasc Med.* 2014;2014:270539.
18. Lejay A, Georg Y, Tartaglia E, et al. Long-term outcomes of direct and indirect below-the-knee open revascularization based on the angiosome concept on diabetic patients with critical limb ischemia. *Ann Vasc Surg.* 2013;pii: S0890-5096(13)00659-6. doi: 10.1016/j.avsg.2013.08.026.
19. Kabra A, Suresh KR, Vivekanand V, et al. Outcomes of angiosome and non-angiosome targeted revascularisation in critical lower limb ischemia. *J Vasc Surg.* 2013;57:44-49.
20. Berclini SA, Chan AK, Pomposelli FB Jr, et al. Efficacy of dorsal pedal artery bypass in limb salvage for ischemic heel ulcers. *J Vasc Surg.* 1999;30:499-508.