

Angiosomes: How Do They Affect My Treatment?

Luis Mariano Palena, MD,^{*} Luis Fernando Garcia, MD,[†] Cesare Brigato, DNP,^{*} Enrico Sultato, DNP,^{*} Alessandro Candeo, RT,^{*} Tommaso Baccaglini, RT,^{*} and Marco Manzi, MD^{*}

The number of diabetic patients is actually increasing all around the world, consequently, critical limb ischemia and ischemic diabetic foot disorders related to the presence of diabetic occlusive arterial disease will represent in the next few years a challenging issue for vascular specialists. Revascularization represents one step in the treatment for the multidisciplinary team, reestablishing an adequate blood flow to the wound area, essential for healing and avoiding major amputations. The targets of revascularization can be established to obtain a “complete” revascularization, treating all tibial and foot vessels or following the angiosome and wound-related artery model, obtaining direct blood flow for the wound. In this article, we summarize our experience in endovascular treatment of diabetic critical limb ischemia, focusing on the angiosome and wound-related artery model of revascularization and the technical challenges in treating below-the-knee and below-the-ankle vessels.

Tech Vasc Interventional Rad 17:155-169 © 2014 Elsevier Inc. All rights reserved.

KEYWORDS angiosome, limb salvage, below-the-knee angioplasty, below-the-ankle vessels, critical limb ischemia, diabetes

Introduction

Critical limb ischemia (CLI) in diabetic patients occurs because of progressive and diffuse obstructive atherosclerosis, most closely associated with tibial and pedal artery involvement. Revascularization represents the first-line treatment, achieving the relief of rest pain and improving wound healing. In recent years, endovascular therapy has earned growing acceptance as a primary strategy for the treatment of infrapopliteal vascular lesions in patients with CLI. However, choosing the correct target for revascularization can represent a critical, complex issue in challenging cases of multilevel arterial disease.

Clinical Evaluation of the Patient

Diabetic patients possess a 12%-25% risk of developing foot lesions,^{1,2} making diabetes the most important risk factor for limb amputation.^{3,4} Advanced atherosclerosis with extensive tibial artery lesions is a common concern in diabetic patients

having CLI and skin wounds. Clinical manifestations range from intermittent claudication to limb-threatening ischemia, rest pain, nonhealing ulcers, and gangrene. Foot lesions may start as an uncomplicated area, but infection can develop, involving soft tissue (cellulitis) and even bones (osteomyelitis), increasing the amputation risk.⁵

The clinical evaluation of patients with foot wounds involves a focused medical history and physical examination, along with appropriate imaging studies and laboratory tests.

Physical examination should provide a foot evaluation and a classification of the lesions. An ischemic foot presents the following typical clinical features: atrophy of the whole foot (skin and muscles), reduction or absence of pedal and tibial pulses, thin and cold skin, and paleness. The typical ischemic diabetic foot includes gangrene of the toes or forefoot, but the hindfoot is often also involved, with heel necrosis. In our daily clinical practice, a transcutaneous oxygen tension (TcPO₂) is used to assess the extent of foot ischemia and it is considered critical when the pressure is <30 mm Hg.⁶

Diabetic foot ulceration needs a clear, descriptive classification system that may be used to direct appropriate therapy and possibly predict the outcome. The “Texas University Wounds Classification” considers the pathogenesis and anatomical aspects of the lesions (Table). Lesions are considered both for depth and for the presence of infection and ischemia. The Texas University Wounds Classification provides a strict correlation between the lesion's grade and stage and the risk of amputation.⁷

^{*}Interventional Radiology Unit, Policlinico Abano Terme, Paduva, Italy.

[†]Vascular Surgery Unit, Clinica de Marly—Hospital military central, Clinica Universitaria Colombia, Bogota, Colombia.

Address reprint requests to Luis Mariano Palena, MD, Interventional Radiology Unit, Policlinico Abano Terme, Piazza C. Colombo 1, Abano Terme, Padova 35031, Italy. E-mail: marianopalena@hotmail.com

Table Texas University Wound Classification. The table describes the type of the lesions according to deepness, presence of infection, and ischemia. The amputation risk is presented as %

University of Texas Wound Classification System	Grade			
	0	I	II	III
	Preulcerative or Postulcerative Lesion Completely Epithelialized	Superficial Wound	Wound Penetrating to Tendon or Capsule	Wound Penetrating to Bone or Joint
Stage				
A No infection or ischemia	0A (0%)	IA (0%)	IIA (0%)	IIIA (0%)
B Infection present	0B (12.5%)	IB (8.5%)	IIB (28.6%)	IIIB (92%)
C Ischemia present	0CI (25%)	IC (20%)	IIC (25%)	IIIC (100%)
D Infection and ischemia present	0D (50%)	ID (50%)	IID (100%)	IIID (100%)

Laboratory evaluation should include renal function assessment, coagulation profile, glucose status, lipid atherogenic profile (small low-density lipoprotein and apolipoprotein B levels and triglyceridemia), and hematocrit and hemoglobin evaluation. The white blood cells must also be assessed to evaluate for the presence of infection as well as the extent of a possible infection.

Imaging studies should be used to assess the peripheral vasculature and to evaluate deep infections of the foot. Color Doppler ultrasound, computed tomography angiography, and magnetic resonance angiography allow the arterial assessment and are important to determine the most appropriate arterial access site for endovascular revascularization. Magnetic resonance imaging of the foot is usually the best way to assess a deep infection, providing an evaluation of possible osteomyelitis.

Indications for the Procedure

Revascularization is a fundamental therapy in patients with CLI because reestablishing an adequate blood supply to the wound is essential for healing and avoiding a major amputation.^{6,8} The most important and principal indications for revascularization are the clinical indications: a nonhealing wound along with $TcPO_2 < 30$ mm Hg and an appropriate imaging vascular assessment. Other indications for treatment include recurrent rest pain, recurrent ulcers, or clinical deterioration of a wound (reversal in the healing process after a previous revascularization).

The target vessels for revascularization should be determined by the wound location on the foot (respective angiosome), and it can be summarized in the following 2 concepts: “complete” and “wound-related artery” (WRA) revascularization (Fig. 1).

It has been demonstrated that “complete” revascularization (Fig. 2) provides better clinical results than “incomplete” revascularization does, with the limb salvage rate at

1 year increasing from 56%, without direct blood flow to the foot (0 below-the-knee [BTK]–patent vessels), to 73%, 80%, and 83% with 1, 2, or 3 BTK–patent vessels, respectively.⁹ Likewise, it has been demonstrated that tibial artery revascularization has a better outcome than treatment of the peroneal artery.¹⁰

With CLI, healing is a blood flow–dependent phenomenon, and the first principle guiding our revascularization strategy must be providing the foot with the best possible blood supply. This statement is particularly true in patients with extensive tissue damage and infection, where the lesion is not confined into a single angiosome space but spreads over contiguous foot spaces and angiosomes.¹¹

Angiosome-oriented revascularization has gained a significant following in the last few years, as a successful revascularization of the artery directly feeding the wound region (WRA) has led to higher rates of limb salvage and wound healing^{12–20} (Fig. 3), but direct revascularization has a different value depending on the capacity of outflow

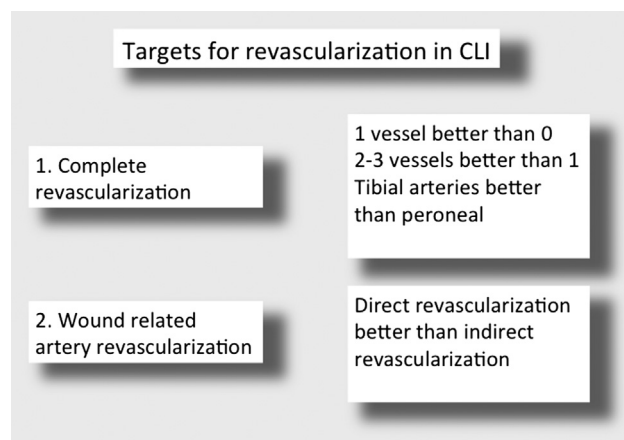


Figure 1 Targets for revascularization in patients with CLI.

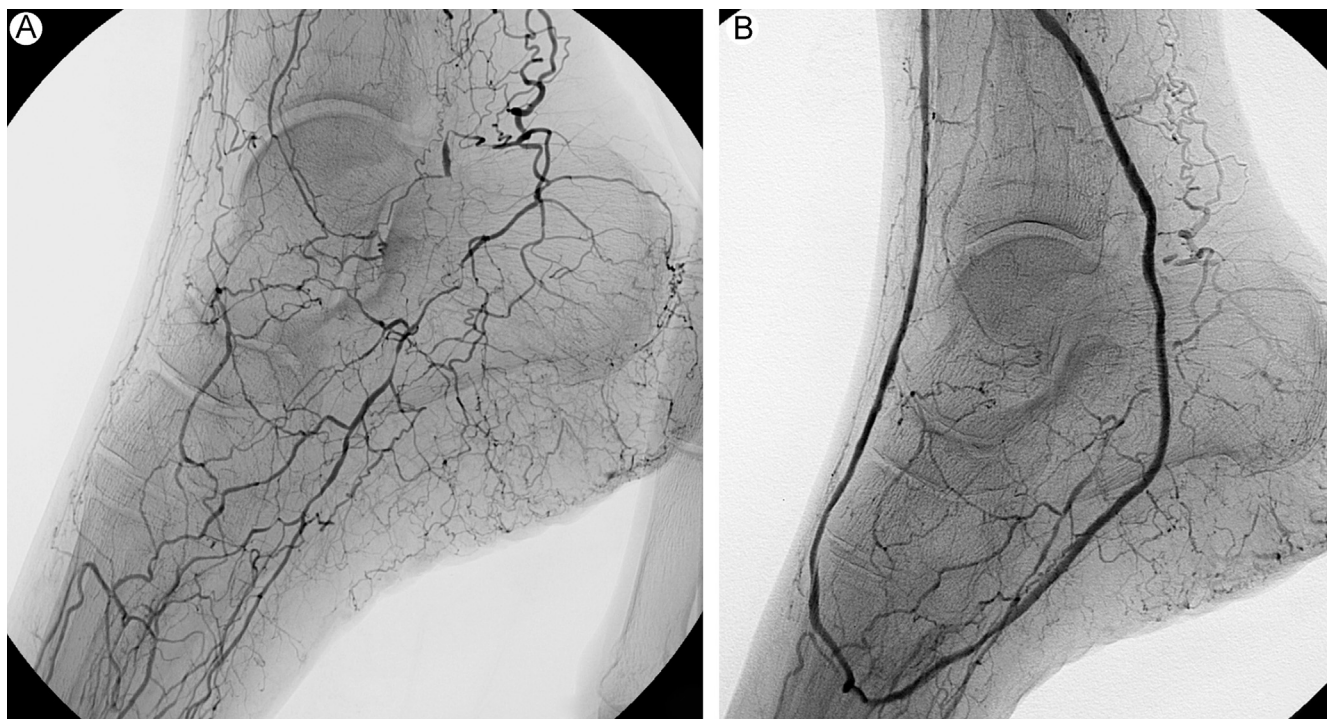


Figure 2 An example of complete revascularization. (A) Baseline angiography showed occlusion of the anterior and posterior tibial arteries and occlusion of the dorsalis pedis and lateral plantar arteries. (B) Final result after balloon angioplasty of anterior and posterior tibial arteries and dorsalis pedis, lateral plantar artery, and plantar arch.

distribution network. Varela et al.²⁰ showed that the restoration of blood flow to the wound through collateral vessels (pedal and peroneal branches) could provide similar results to those obtained through its specific source artery in terms of healing and limb salvage (Fig. 4). Conversely, patients with diffuse disease of the small distal

vessels (patients with diabetes and end-stage renal disease) could need a direct blood flow to the WRA for healing.²¹

The WRA concept is of particular value in cases of lesions confined to a single angiosome (toe lesions) or in cases of postsurgical wounds such as forefoot amputations (rays, transmetatarsal, Lisfranc, and Chopart amputations)

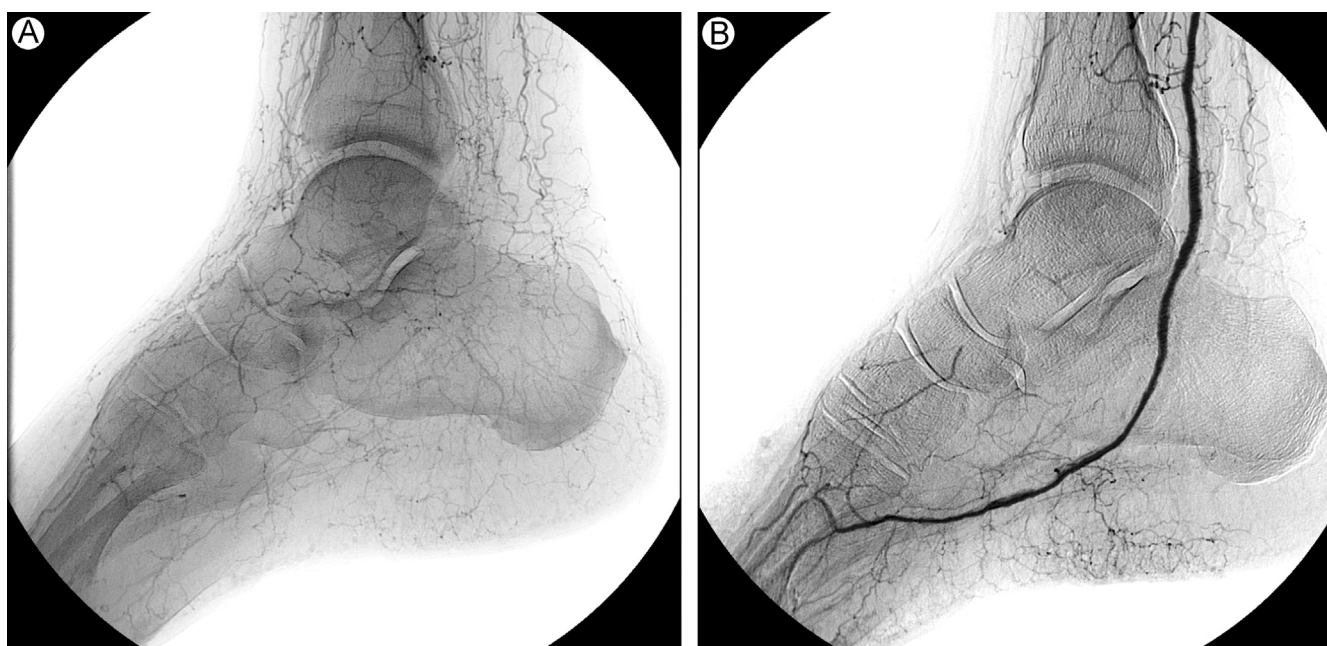


Figure 3 An example of wound-related artery revascularization. (A) Baseline angiography showed a "desert foot" with occlusion of anterior and posterior tibial arteries and occlusion of dorsalis pedis and plantar arteries. (B) Final result after balloon angioplasty of posterior tibial and lateral plantar arteries: restoration of a direct blood flow to the forefoot plantar ulcer.

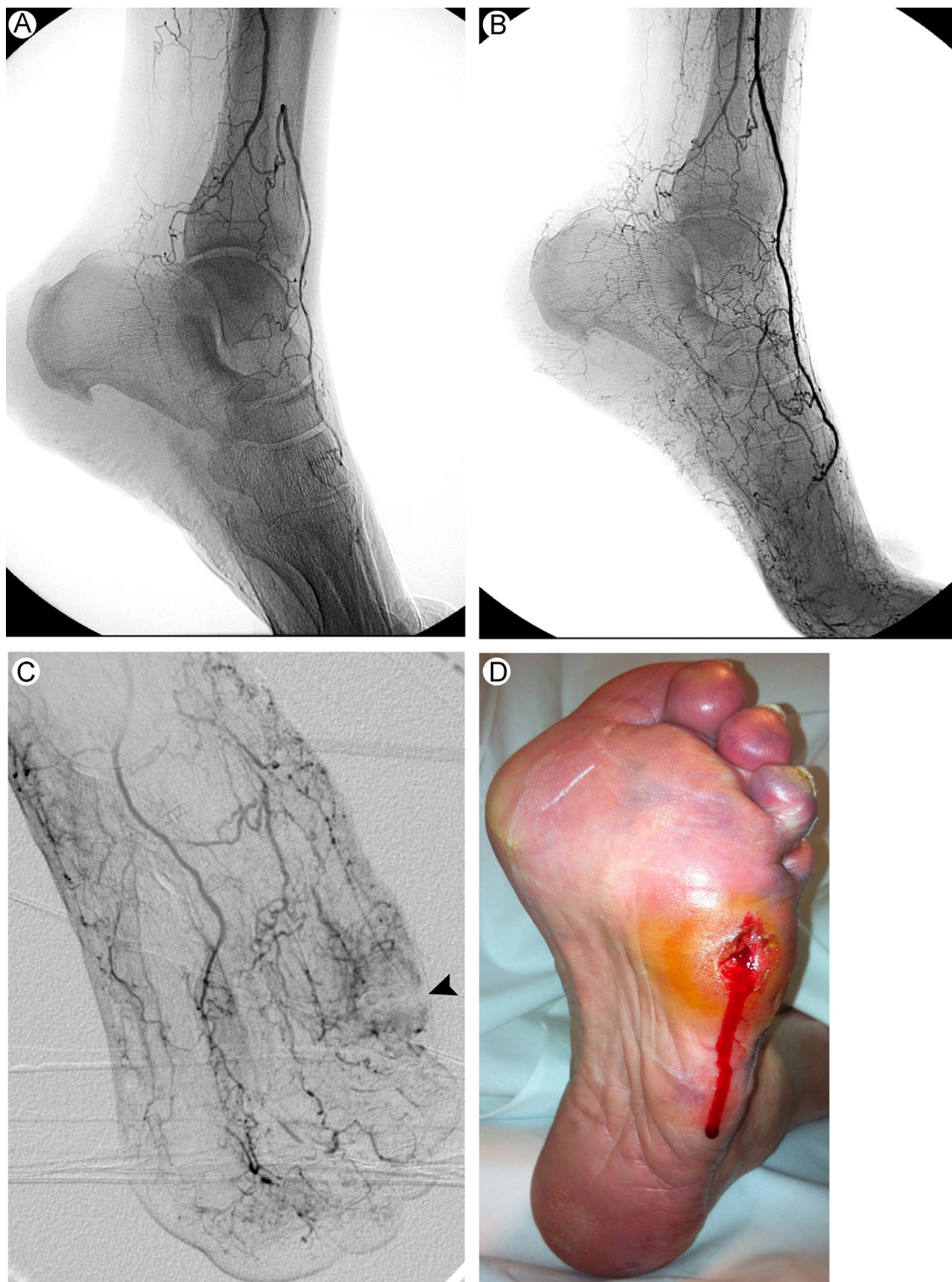

Figure 4 An example of indirect revascularization. (A) Baseline angiography showed occlusion of anterior and posterior tibial arteries and distal occlusion of dorsalis pedis and complete occlusion of plantar arteries. (B) Final result after balloon angioplasty of anterior tibial and dorsalis pedis arteries, with indirect blood flow for the plantar ulcer. (C)—black arrowhead shows the blush in the wound area). (D) Bleeding in the ulcer area can be noted after revascularization. (Color version of figure is available online.)

that often interrupt the connection between the dorsal and the plantar circulation. In these cases, the revascularization should supply the surgical flap, therefore supporting surgical wound healing (Fig. 5). The revascularization strategy is planned with the objective of providing a direct,

in-line (ie, noncollateral) blood supply to the foot (specifically, to the angiosome of any ischemic lesion), considering that the vascular anatomy of the leg and the foot is composed of 2 circulatory pathways that are connected through the plantar arch (Fig. 6). Specifically, the anterior

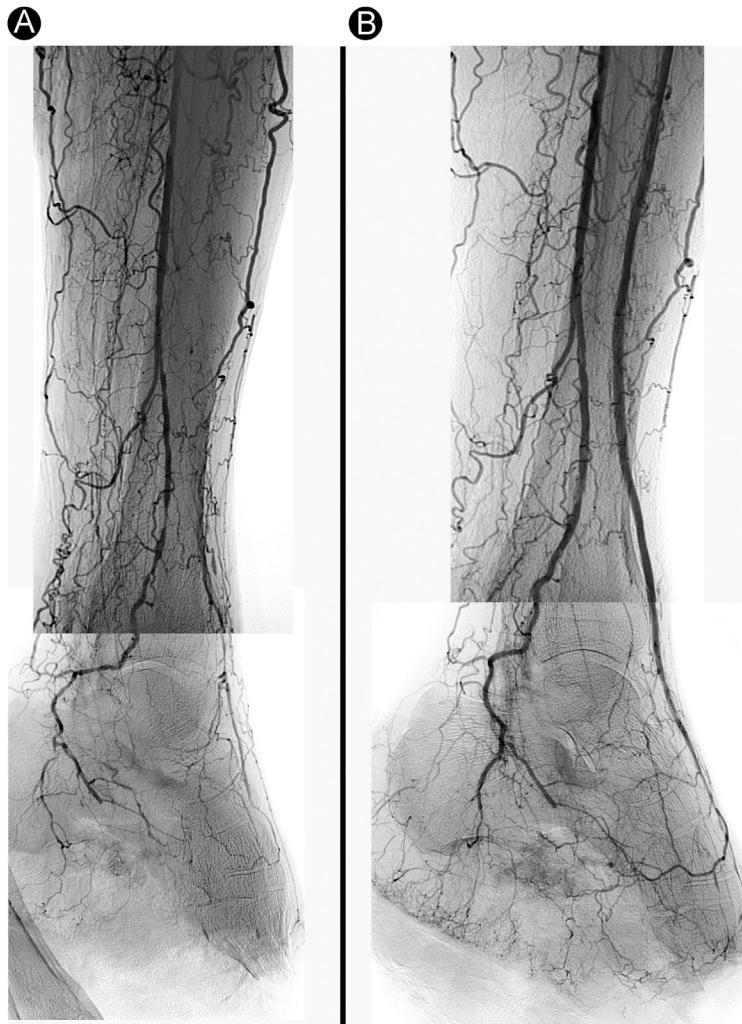

Figure 5 An example of surgical wound-related revascularization. (A) Baseline angiography showed occlusion of anterior tibial artery and stenosis of peroneal artery in a patient who underwent transmetatarsal amputation. (B) Result after balloon angioplasty of peroneal and anterior tibial arteries and dorsalis pedis and plantar arteries.

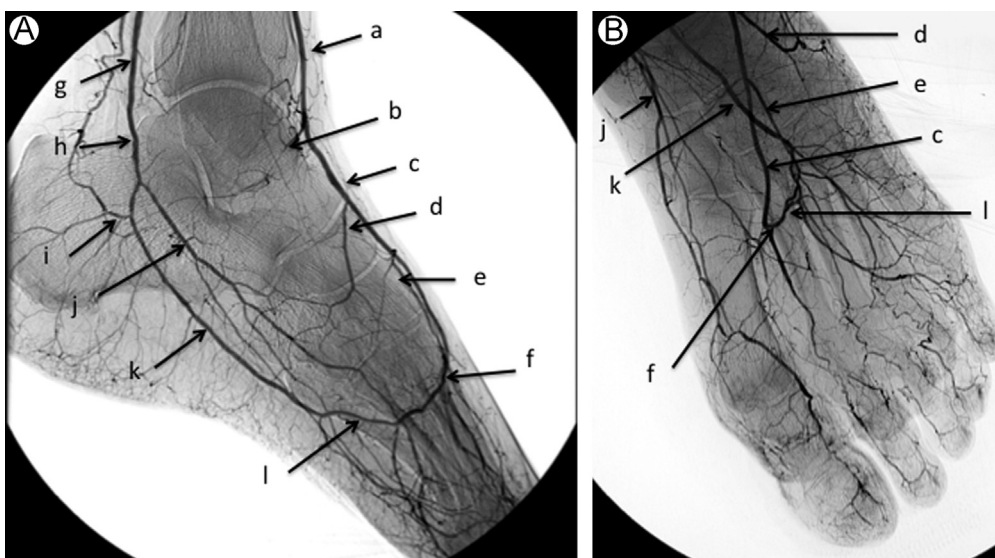


Figure 6 An example of normal vascular anatomy of the foot. (a) Distal anterior tibial artery, (b) malleolar artery, (c) dorsalis pedis artery, (d) lateral tarsal artery, (e) arcuate artery, (f) deep perforating artery, (g) distal posterior tibial artery, (h) common plantar artery, (i) medial calcaneal branch, (j) medial plantar artery, (k) lateral plantar artery, and (l) plantar arch.

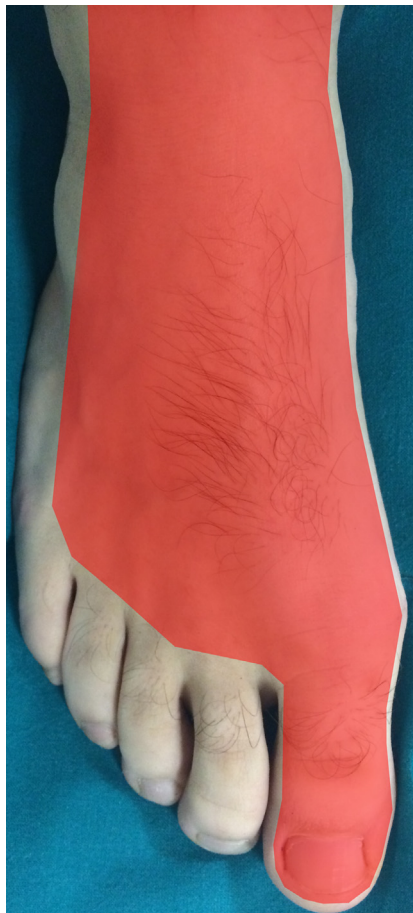

Figure 7 Anterior pedal angiosome. The dorsum of the foot is supplied by the anterior circulation (red). (Color version of figure is available online.)

tibial artery gives rise to the anterior and dorsal circulation of the foot, whereas the posterior tibial artery supplies flow to the posterior and plantar circulation of the foot. Both tibial arteries, together with the peroneal artery, supply different regions of the foot and the ankle.²²

Dorsal Angiosomes

The entire dorsal part of the foot is functionally connected in a single angiosome, supplied by the dorsal circulation. The principal vessel in this angiosome is the dorsalis pedis artery, which arises from the anterior tibial artery and gives off the medial malleolar, lateral malleolar, medial and lateral tarsal, and arcuate arteries. The dorsum of the foot and the toes as well as the upper anterior perimalleolar region are nourished by the dorsalis pedis and its branches (Fig. 7).

Plantar Angiosomes

The posterior and plantar circulation, supplied by the posterior tibial artery, feeds 3 different angiosomes. The medial calcaneal artery is the first vessel of the posterior circulation that originates from posterior tibial artery; this branch supplies the medial malleolar region and the medial plantar heel.

The angiosome supplied by the medial plantar artery includes the medial plantar instep. The medial plantar artery has a superficial branch that perfuses the dorsum of the foot and is often connected to the anterior circulation through the medial tarsal arteries. Furthermore, its deep branch might be connected to the first plantar metatarsal artery, which supplies the first toe.

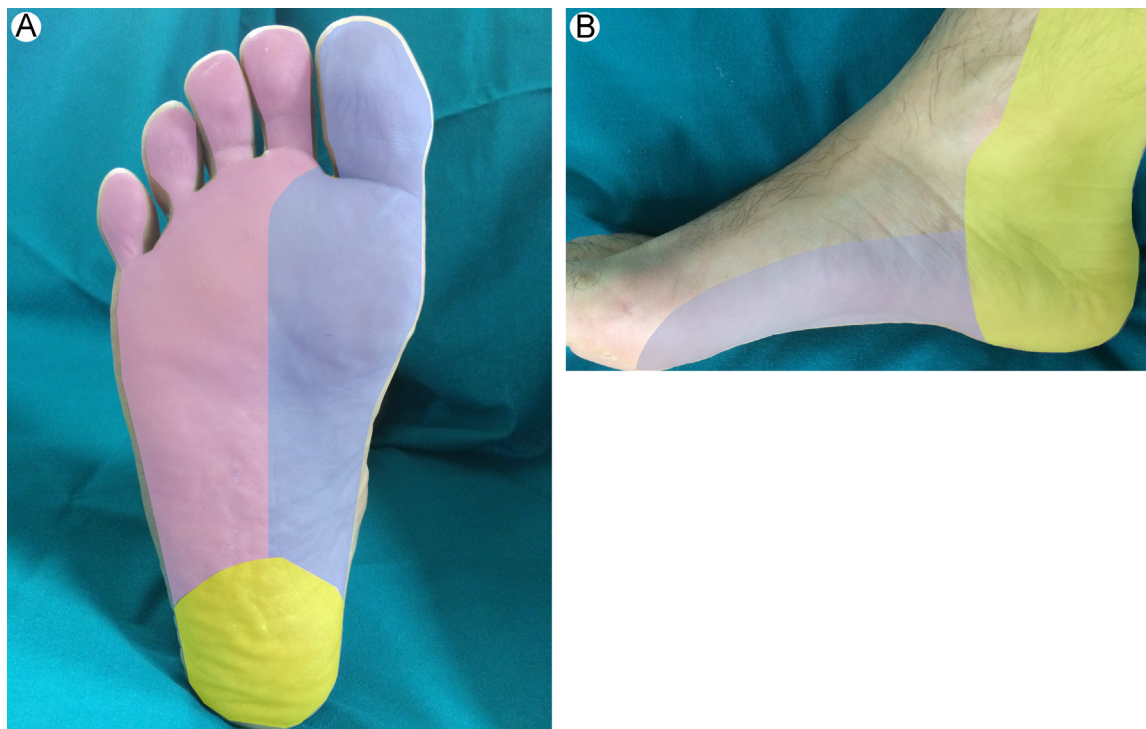


Figure 8 Posterior and plantar angiosome. (A) Plantar view and (B) medial view. The angiosome of the medial plantar artery (light blue), the angiosome of the lateral plantar artery (pink), and the angiosome of the medial calcaneal artery (yellow). (Color version of figure is available online.)

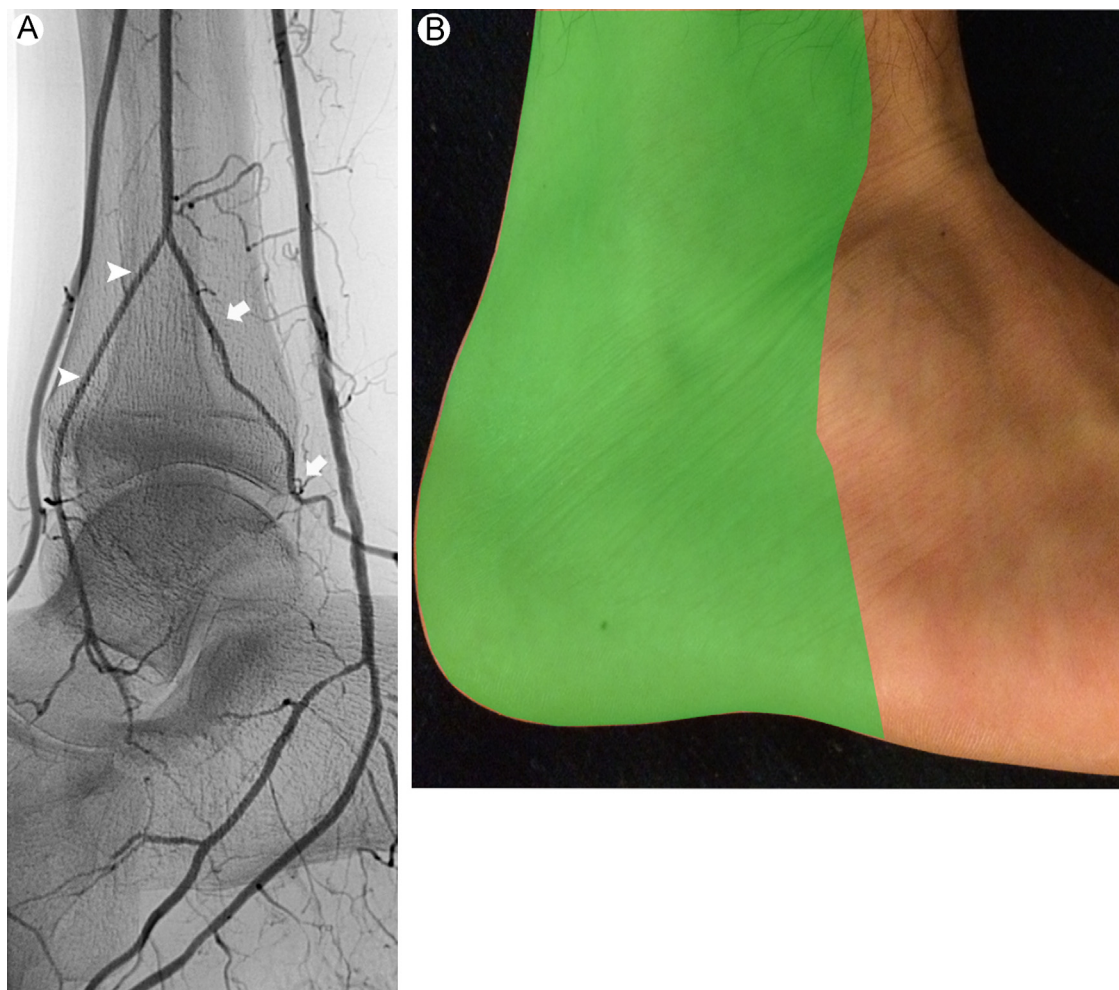


Figure 9 Peroneal angiosome. (A) Lateral oblique angiography shows the bifurcation of the peroneal artery into anterior perforating (arrowhead) and lateral calcaneal (arrows) branches. (B) Angiosome of the peroneal artery (green). (Color version of figure is available online.)

The lateral plantar artery communicates with dorsal circulation through the plantar arch and the deep perforating artery. The plantar metatarsal arteries originate from the plantar arch and feed the digital artery in the forefoot, which in combination with the lateral plantar surface constitutes the lateral plantar angiosome (Fig. 8).

Peroneal Angiosome

At the level of the malleolus, the peroneal artery bifurcates into anterior perforating and lateral calcaneal branches, each of which supplies a specific angiosome. The anterior branch of the peroneal artery supplies the anterior-lateral ankle angiosome, and the calcaneal branch of the peroneal artery supplies the lateral heel angiosome (Fig. 9).

Procedure Steps

Proper evaluation of the foot vessels during diagnostic angiography and then proper treatment of these vessels represent the key steps in orientating a successful revascularization strategy in patients with CLI.

At 3 days before of the procedure, the patients are pretreated with aspirin (75-160 mg) and ticlopidine (500 mg) or clopidogrel (300 mg). After administration

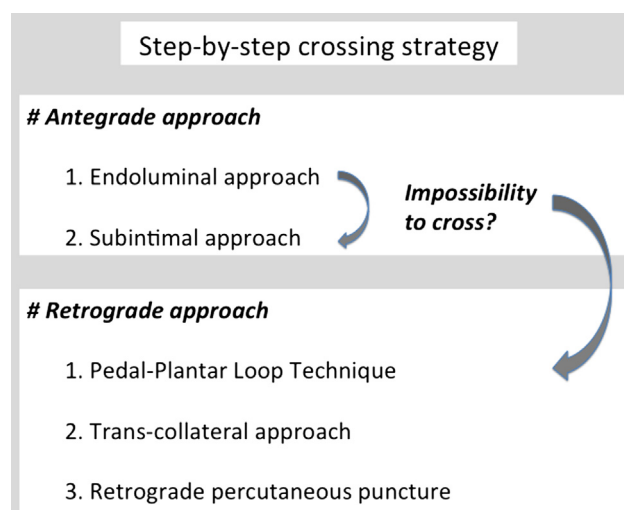


Figure 10 Step-by-step crossing strategies. (Modified with permission from Ferraresi et al.¹¹)

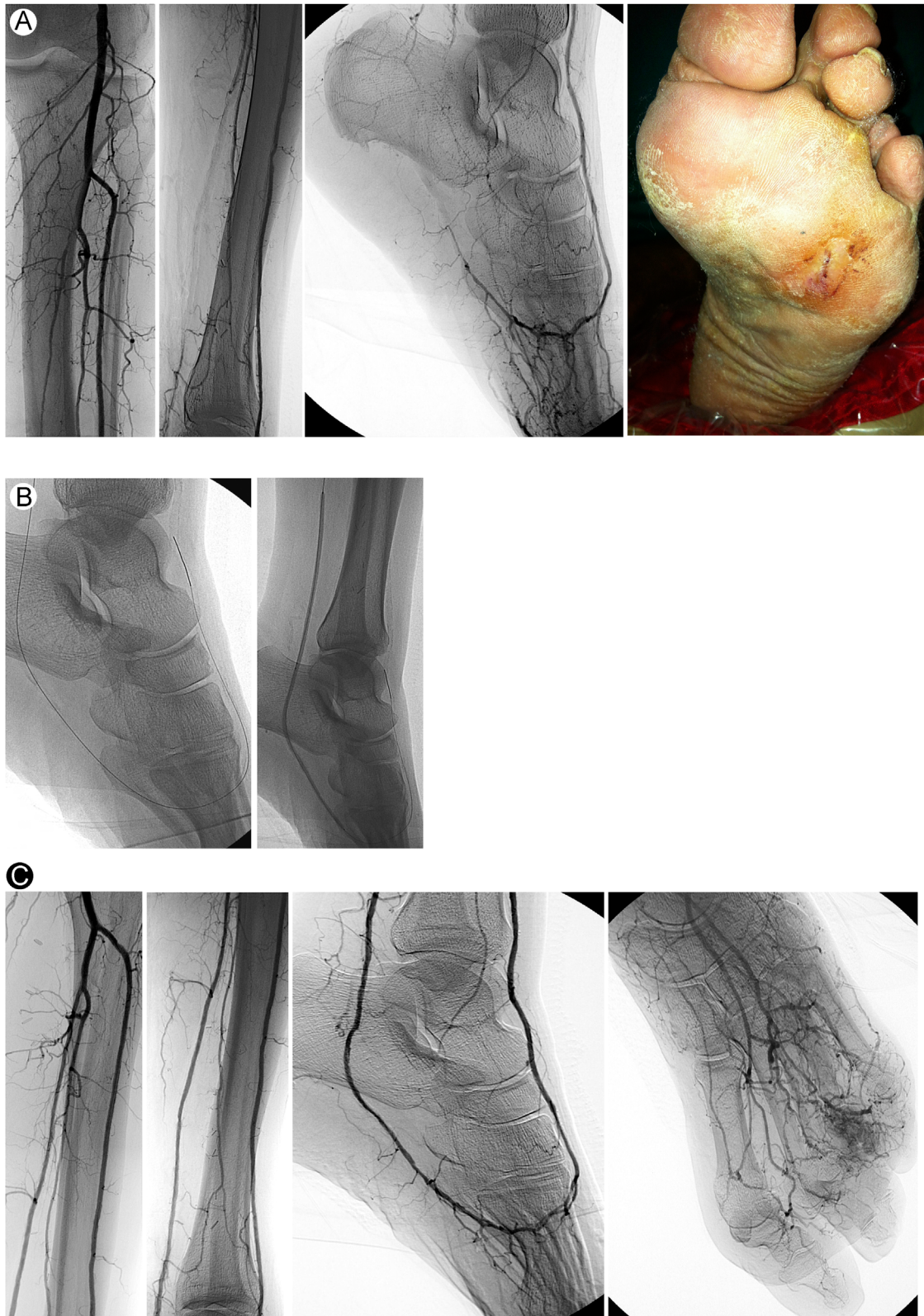


Figure 11 An example of intraluminal approach. (A) Baseline angiography showed occlusion of posterior tibial and lateral plantar artery in a patient with plantar wound. (B) Angiosome-guided recanalization with intraluminal crossing of posterior and lateral plantar arteries with 0.014-in wire and balloon angioplasty. (C) Results with patency of posterior and plantar arteries, direct blood flow, and ulcer blush. (Color version of figure is available online.)

of local anesthesia, if anatomically possible, an antegrade access into the common femoral artery is obtained under ultrasound guidance (7.5 MHz linear probe), and a 5-F

sheath is deployed. During the procedure, the patients are typically managed with 5000 units of unfractionated heparin.

The target vessel for treatment is chosen according to the angiosome and WRA concepts, according to the clinical indications and identification of potential surgical targets, after a comprehensive angiographic evaluation of the foot vascular anatomy and the distal distribution and collateral network.

The next step in percutaneous recanalization is to successfully cross any long vascular obstructions that are typical of patients with CLI. Recanalization can be performed using endoluminal, subintimal, and retrograde techniques (Fig. 10).^{11,23}

Antegrade Recanalization

Specifically, the endoluminal approach is our first choice in every type of lesion, because it is often possible to cross long BTK lesions by maintaining the endoluminal position (Fig. 11). It is the preferred approach in calcified vessels. Our choice of wire is usually a soft tip, 0.014 in, hydrophilic guidewire and support catheter or catheter balloon. When our traditional endoluminal revascularization fails, we then change our strategy according to the vessel lesion. In the case of calcified vessels or short-length obstructions, we prefer to pursue the endoluminal approach using the

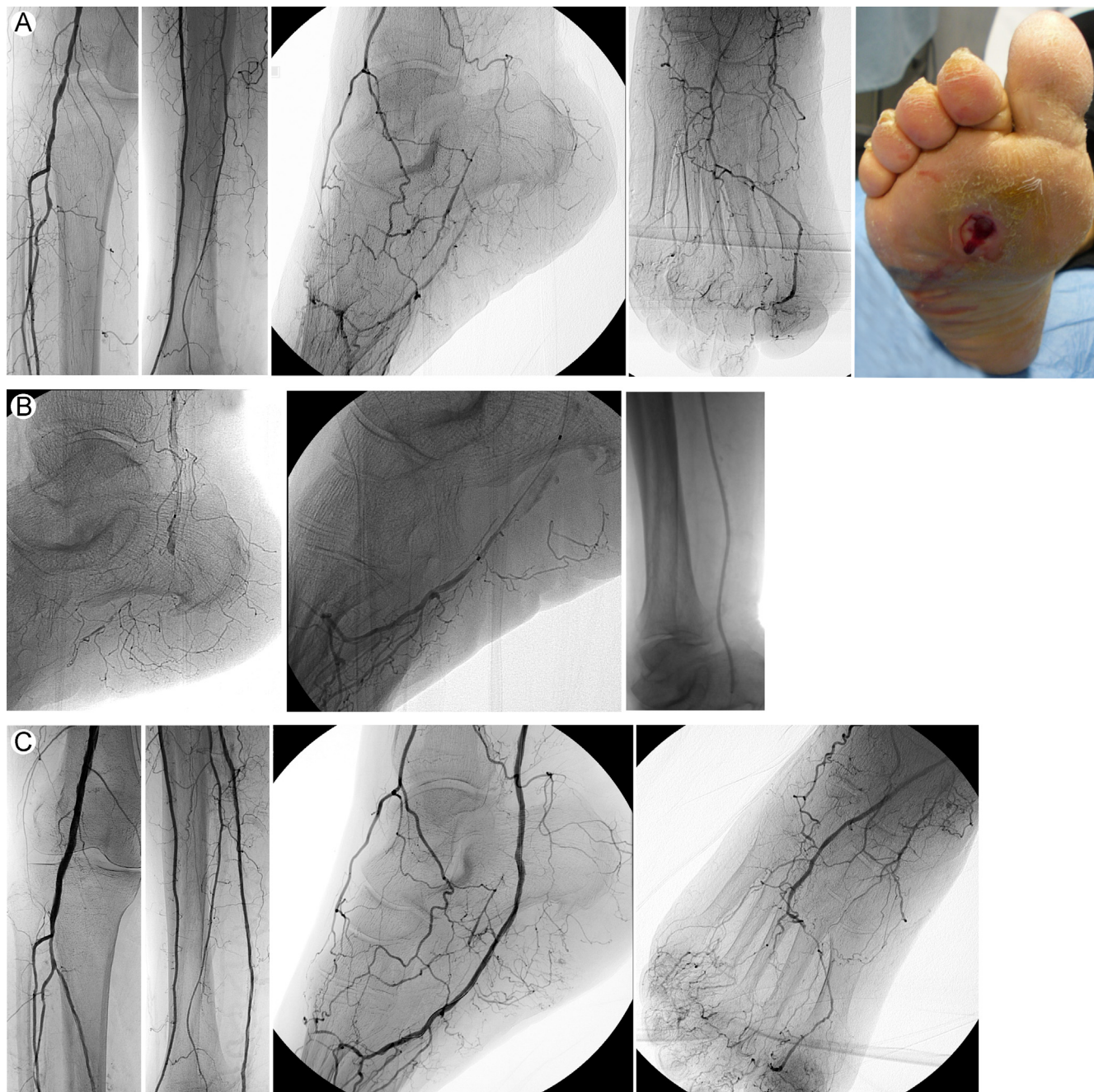


Figure 12 An example of subintimal approach. (A) Occlusion of posterior and plantar arteries in a patient with plantar wound. (B) Angiosome-guided treatment. Subintimal recanalization of the posterior and lateral plantar artery with successful reentry in the distal plantar artery. (C) Final results after balloon angioplasty. (Color version of figure is available online.)

parallel wires technique and dedicated chronic total occlusions (CTOs) guidewires.^{11,23}

In case of a long CTO or a noncalcified or spot-calcified vessel, we shift to a subintimal approach.

The subintimal approach can be safely and effectively used to achieve a successful revascularization²⁴ (Fig. 12). It is usually performed using 0.035- or 0.018-in guidewire in the tibial vessels and 0.018- or 0.014-in guidewire in the foot arteries and a support catheter or a catheter balloon. It is usually performed by pushing the guidewire to create

a loop shape and following the loop with a support catheter to dissect the subintimal space until the reentry point. At the reentry point, the main imperative is to avoid damaging the healthy distal vessels. We manage the reentry by pushing the looped wire toward the patent distal vessel in a location where the patent distal lumen is straight and free from calcium. In the case of a calcified vessel, a poor landing zone, or a patent distal vessel that is suitable for a bypass, we preferred to approach it using a CTO-dedicated wire or retrograde approach.

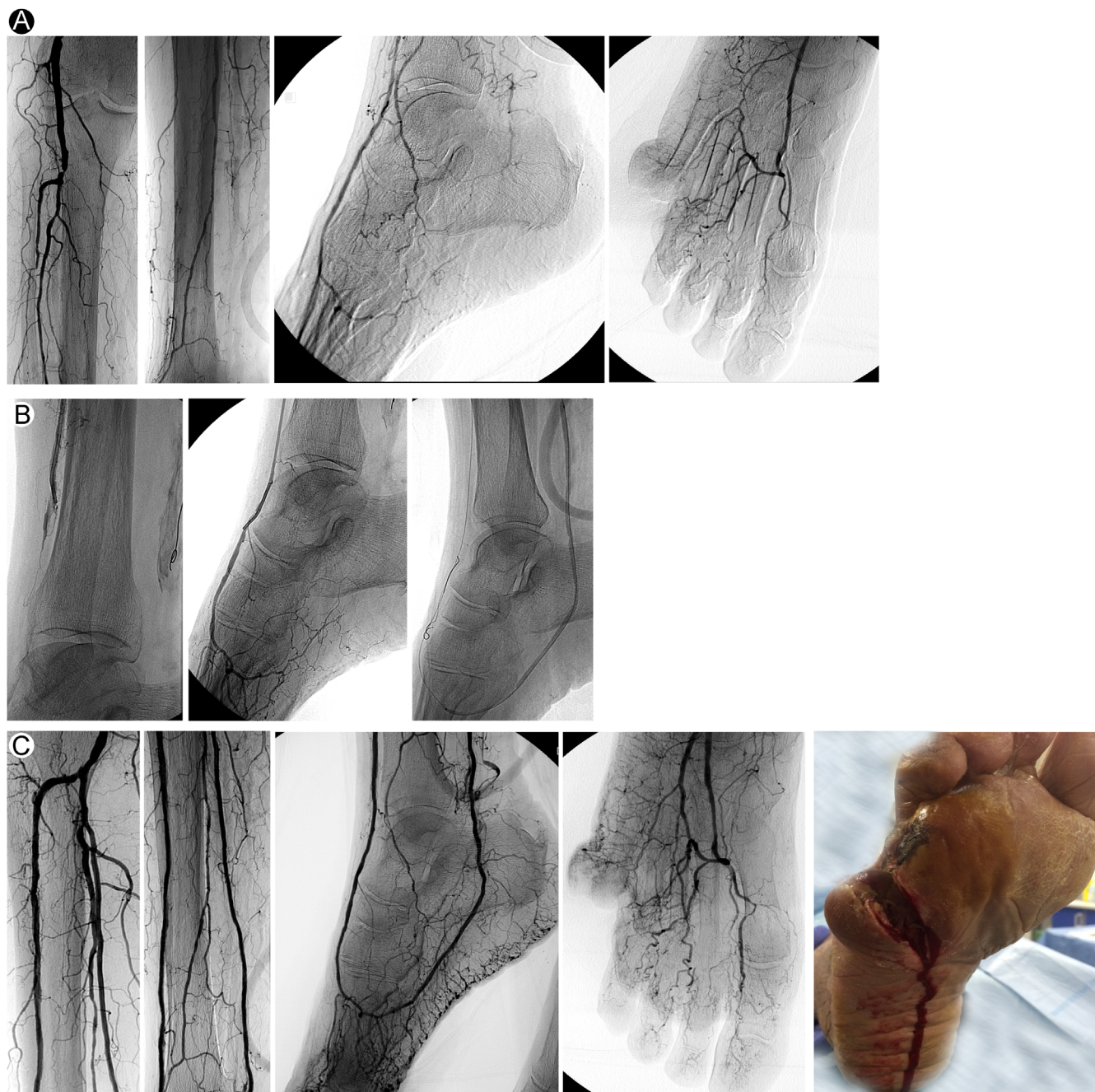


Figure 13 An example of the pedal-plantar loop technique. (A) Basal angiography showed occlusion of anterior and posterior tibial arteries and occlusion of plantar arteries in a patient with open amputation in the fifth toe. (B) Angiosome-guided revascularization. Subintimal approach of the posterior tibial artery failed, subintimal approach of the anterior tibial artery with successful reentry, followed by retrograde recanalization of lateral plantar and posterior tibial arteries and balloon angioplasty. (C) Final results showed patency of all the tibial and foot vessels, with direct blood flow for the wound and bleeding after the procedure. (Color version of figure is available online.)

Retrograde Approach

When the antegrade recanalization techniques fail, retrograde recanalization is considered. The technical options for retrograde approaches are different.

The Pedal-Plantar Loop Technique

This technical strategy aims to restore a direct arterial inflow from both principal circulatory pathways of the foot, achieving a complete below-the-ankle (BTA) revascularization, but it can also be used to perform a WRA recanalization, crossing through the opposite patent circulatory pathway to obtain a retrograde recanalization of the occluded foot vessel.

It is based on the technique of successfully advancing a wire followed by a balloon through the plantar arch,

recreating a loop or patent communication from the dorsal to the plantar circulation of the foot (or vice versa)^{25,26} (Fig. 13). This technical strategy has been thoroughly tested and proven to be useful for recanalization of patients with CLI due to BTK and BTA atherosclerotic disease,²⁷ providing a high rate of acute success, achieving adequate angiographic results, without significant periprocedural complications.

Transcollateral Recanalization

In many cases of extreme vascular intervention, it is not possible to perform regular antegrade recanalization of occluded tibial and foot arteries. The solution, when possible, is to attempt less traditional techniques,²⁸⁻³⁰

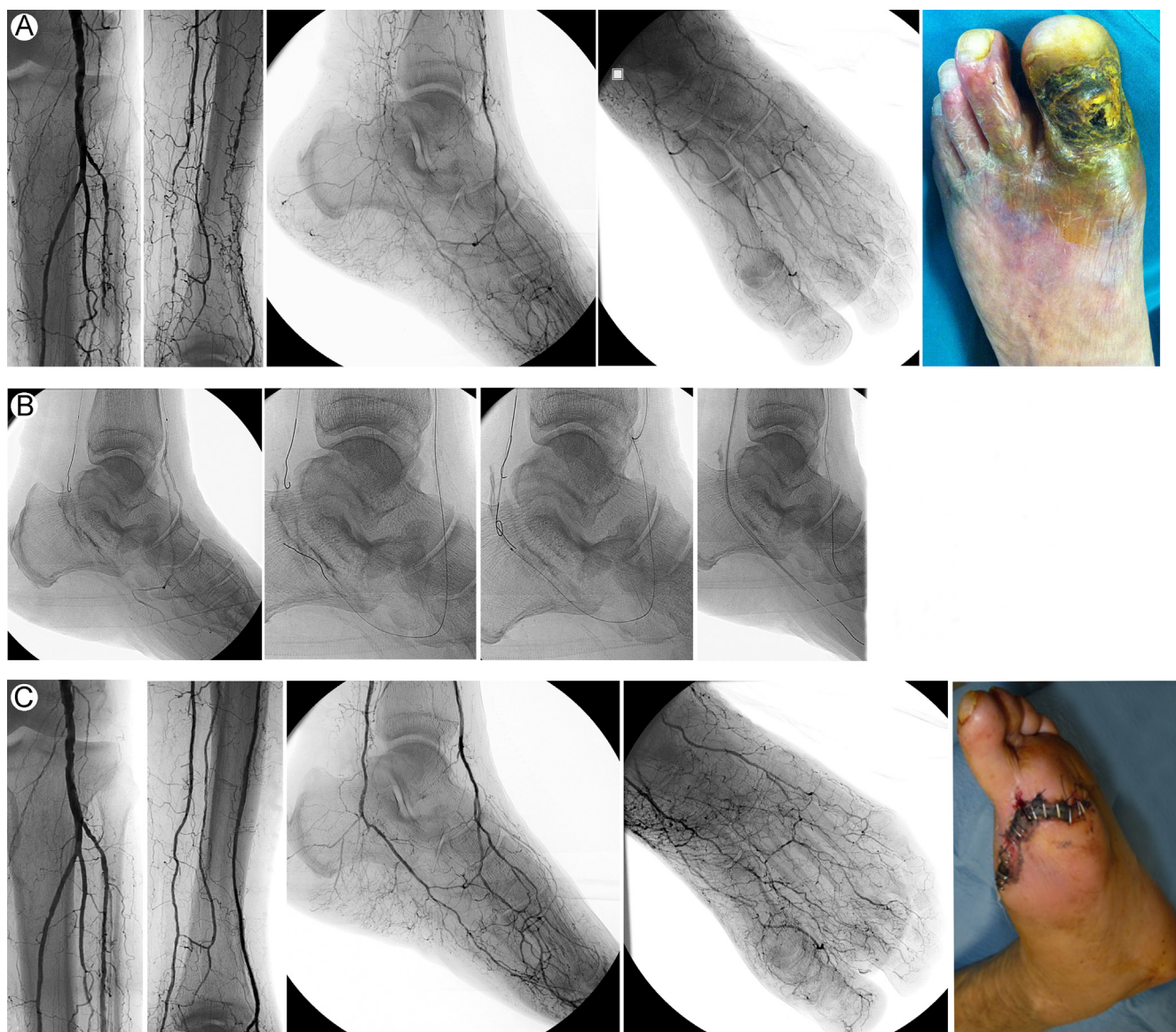


Figure 14 An example of the transcollateral technique. (A) Baseline angiography showed occlusion of anterior and posterior tibial arteries and occlusion of dorsalis pedis and lateral plantar arteries in a patient with ulcer in the first toe. (B) Angiosome-guided treatment. Failure of antegrade attempt to recanalize posterior tibial artery. Antegrade recanalization of anterior tibial artery and retrograde recanalization of medial plantar and posterior tibial arteries, followed by antegrade angioplasty. (C) Result with patency of all tibial vessels and direct blood flow for the wound through the medial plantar artery. The patient underwent first metatarsal amputation. (Color version of figure is available online.)

such as the transcollateral approach, consisting of using a natural anastomosis (collateral) to allow access to recanalize a tibial or foot artery.

Different anastomosis can be used for this purpose:

- (1) The “deep arch” of the foot (which communicates the medial plantar artery with lateral tarsal branch) can be used to recanalize the dorsal or plantar circulation or to recreate the pedal arch, through the tarsal branch (Fig. 14).

- (2) Distal peroneal artery branches can be used to access the tibial and foot arteries.

Retrograde Percutaneous Puncture

This strategy consists of a percutaneous puncture of the distal patent vessel followed by the retrograde guidewire advancement, with the aim of achieving a proximal patent lumen of the target artery^{11,31} (Fig. 15).

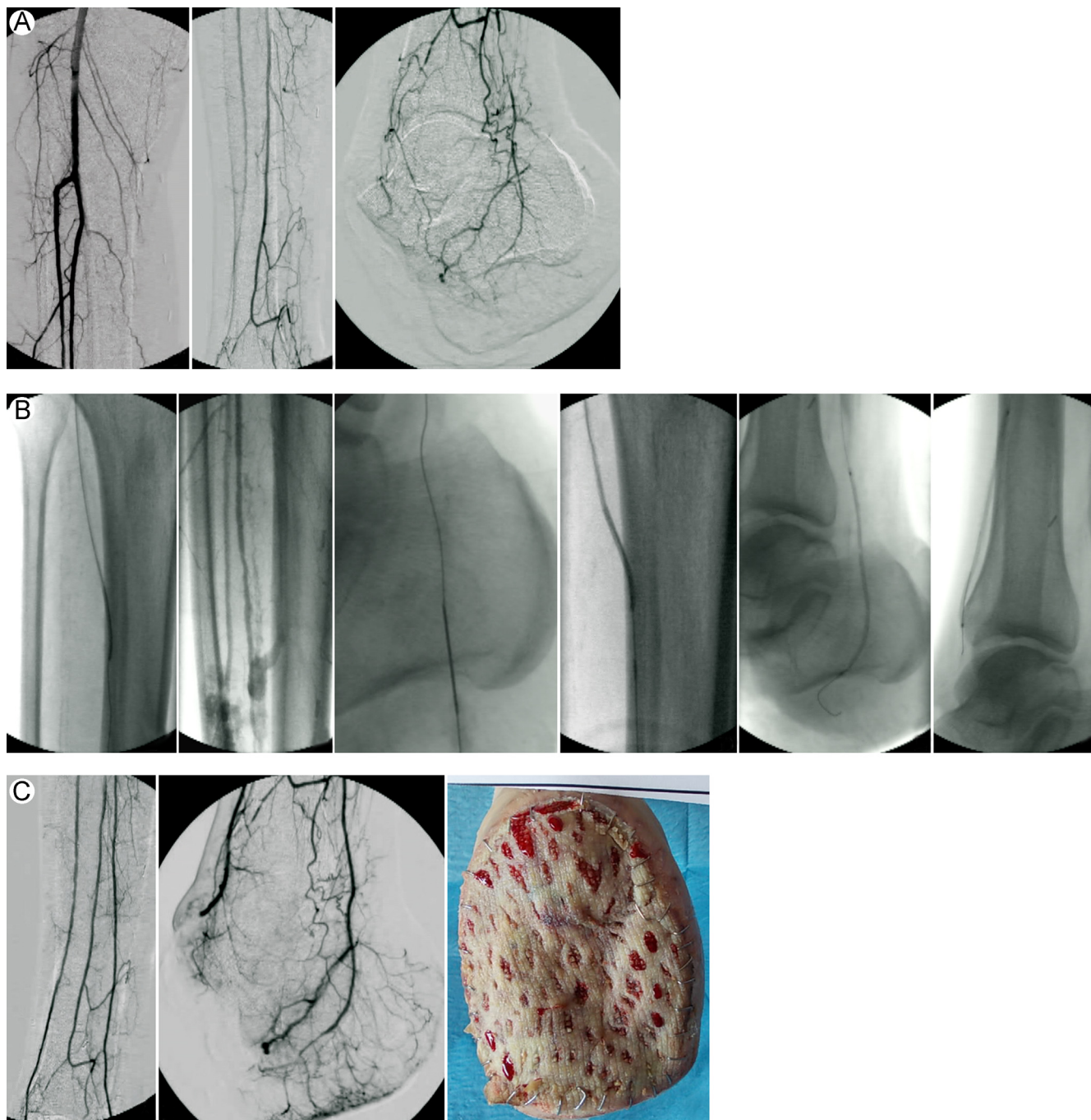


Figure 15 An example of retrograde percutaneous approach. (A) Baseline angiography showed occlusion of the anterior and posterior tibial arteries in a patient who underwent Chopart amputation. (B) Surgical angiosome-guided procedure. After failure of the antegrade approach of posterior tibial artery, retrograde puncture of lateral plantar artery and retrograde recanalization, followed by antegrade angioplasty and antegrade recanalization of anterior tibial artery. (C) Final results with patency of all tibial and foot residual vessels. Patient underwent skin graft. (Color version of figure is available online.)

Specifically, to perform percutaneous retrograde distal access, several technical keys are important. Proper puncture site selection requires accurate and meticulous angiographic evaluation using the proper projections. Vascular spasm can compromise the puncture and subsequent guidewire advancement within the small vessels. Pharmacologic support and proper technique to avoid spasm are essential. The use of vasodilators (nitroglycerine and verapamil) is mandatory. Careful vascular puncture should be performed with a 21-gauge needle that is 4 cm in length, under fluoroscopic guidance with contrast medium injection and at maximum magnification or direct sonographic guidance after careful evaluation with fluoroscopy. For the retrograde crossing, we traditionally prefer a 0.018-in guidewire because of the enhanced support. The guidewire is used in combination with a low-profile support catheter. Upon reaching the proximal patent arterial segment, the aim is to perform a rendezvous with an antegrade catheter. When the rendezvous is obtained,

the retrograde wire is externalized. After reversing, the wire hemostasis is obtained by advancing a balloon catheter beyond the puncture site and inflating it to nominal pressure.

Overcoming Technical Challenges

The previously described strategies may fail or prove to be unfeasible especially when the distal vessels are also diseased. To further improve success rates of angioplasty for challenging BTK and BTA disease, a novel revascularization technique has been conceived.^{32,33} When the tibial or pedal arteries are occluded and not available for puncture, retrograde percutaneous transmetatarsal artery access is a useful alternative to retrograde recanalization of foot and tibial vessels. These maneuvers can improve both technical and clinical results for nonsurgical

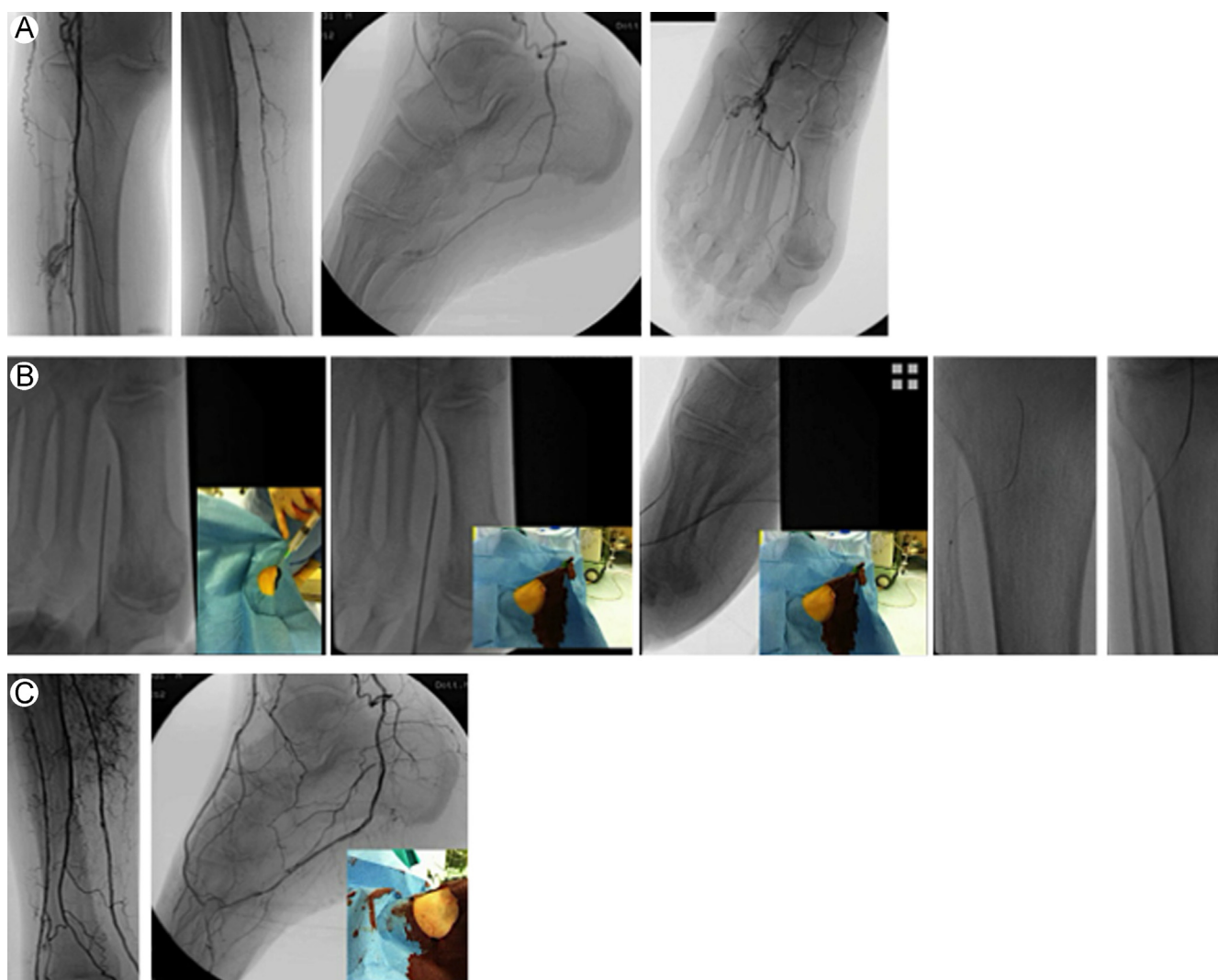


Figure 16 An example of transmetatarsal access. (A) Baseline angiography showed occlusion of the anterior and pedal artery in a patient with wounds in the second and third toes. (B) Angiosome-guided procedure. After failure to cross the anterior tibial artery, retrograde transmetatarsal access was performed in the first metatarsal artery, followed by retrograde recanalization of dorsalis pedis and anterior tibial arteries. (C) Final result after balloon angioplasty showed patency of all tibial and foot arteries. (Color version of figure is available online.)

candidates,^{32,33} providing a significant improvement in the TcPO₂ value and 81.5% of amputation-free survival rate at 12 months (Fig. 16).

These extreme accesses are performed after pharmacologic support to avoid spasm. Diluted verapamil is injected intra-arterially, as distal as possible, close to the foot. Local anesthesia is administered close to the target area, and diluted verapamil together with lidocaine is injected into the subcutaneous tissue. The best site to perform the access is at the dorsum of the foot via the first dorsal metatarsal artery. By way of the dorsal branch of the first metatarsal artery, it is usually possible to reach the plantar arch, and across the arch, it is possible to recanalize the dorsalis pedis or lateral plantar artery.

The puncture is performed with a 21-gauge needle under fluoroscopic guidance with contrast medium injection and at the maximum magnification, and a 0.018-in guidewire is deployed. After access creation, retrograde intraluminal recanalization of the metatarsal artery and plantar arch is performed followed by intraluminal or subintimal recanalization of the foot and tibial vessel and rendezvous technique. The procedure is completed from the antegrade access, passing a guidewire beyond the puncture site, and gently inflating a catheter balloon, achieving hemostasis at the metatarsal artery level.

Postprocedure Care and Clinical Follow-up

Administration of aspirin is continued indefinitely and ticlopidine or clopidogrel is continued for 3 months.

After revascularization, patients underwent surgical debridement of the lesions, including ulcerectomy and sequestrectomy of the infected bones, and when needed, soft tissue reconstruction by applying negative-pressure wound therapy, dermal substitutes, and autologous skin graft. Preventive care is also carried out along with prophylactic surgery and foot deformities correction.

After discharge, clinical follow-up is routinely performed at 2-week intervals until complete healing and shoes customization. Then, it is continued at intervals of 1-3 months, performing TcPO₂ control, education, and primary and secondary prevention.

Expected Outcomes

The expected outcomes of revascularization are to reestablish an adequate blood flow to the wound area, allowing for healing and avoiding major amputations. Direct revascularization, oriented by the angiosome and WRA concept, should be pursued especially in patients with an inadequate distal distribution system, because of the reduced or absence of collateral vessels formation or the occlusion of the foot vessels (patients with “desert foot,” Fig. 3) and also in patients with forefoot amputations in whom the foot circulation patterns are interrupted and become terminal circulations.

The angiographic end point after endovascular treatment may be the presence of a wound blush³⁴ that can be considered a novel positive predictive factor for healing and for limb salvage in patients with CLI. However, the converse, the lack of a wound blush, does not represent a

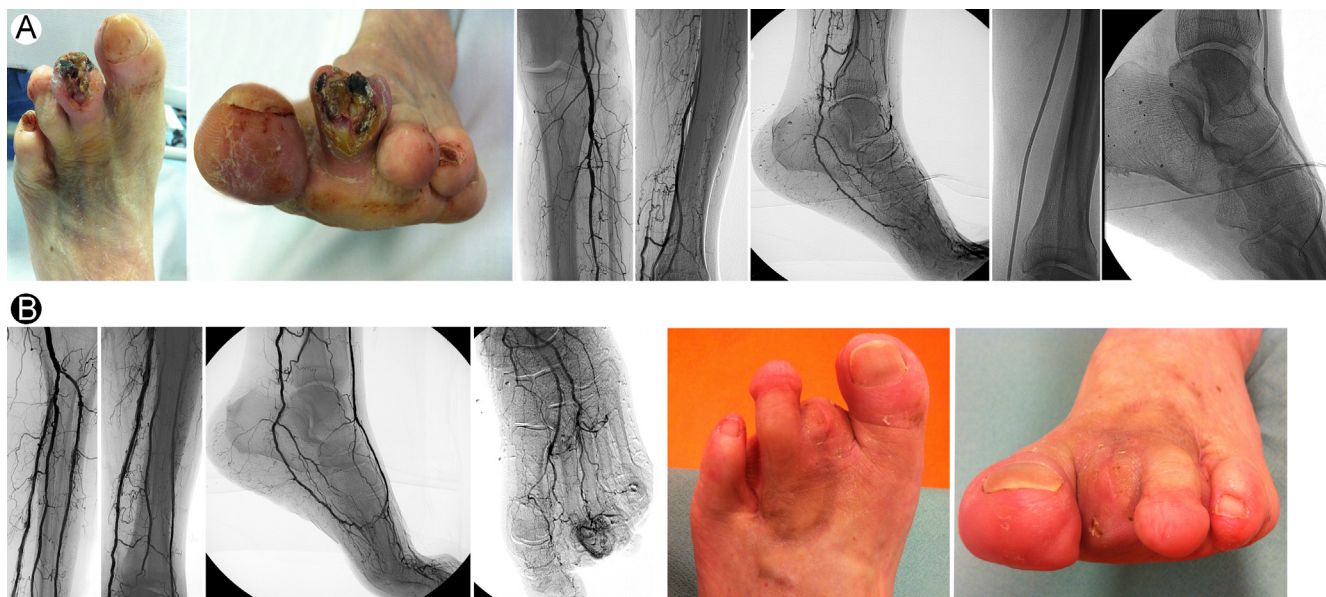

Figure 17 An example of expected outcomes after the angiosome-guided procedure. (A) A patient with IIIID TUC wound in the second toe, previously amputated in the forth toe. Baseline angiography showed occlusion of anterior and posterior tibial arteries and occlusion of dorsalis pedis. The occluded vessels were treated by balloon angioplasty. (B) Final result showed patency of anterior and posterior tibial arteries, patency of dorsalis pedis, and evident blush for the lesion through plantar and dorsal branches. The patient underwent amputation of the second toe, and after 2 months, the surgical incision healed. The patient maintained the maximum amount of the plantar stand and the walking capability. TUC, Texas University Wounds Classification. (Color version of figure is available online.)

negative prognostic factor, especially after a subintimal treatment, where a diffuse vessel spasm with slow flow is frequent, inhibiting tissue blush. The lack of a wound blush can also be explained after the restoration of blood flow to a long arterial segment, such as in long chronic occlusion, and the necessity of the microcirculation to adapt to this new blood flow.

The clinical expected outcome is to achieve the limb salvage, free of amputation or at least preserving the maximum amount of the plantar stand to allow and maintain the capability of walking (Fig. 17).

References

- Singh N, Armstrong DG, Lipsky BA: Preventing foot ulcers in patients with diabetes. *J Am Med Assoc* 293:217-228, 2005
- Abbott CA, Garrow AP, Carrington AL, et al: Foot ulcer risk is lower in South-Asian and African-Caribbean compared with European diabetic patients in the UK: The north-west foot care study. *Diabetes Care* 28:1869-1875, 2005
- Ragnarson Tennvall G, Apelqvist J: Health-economics consequences of diabetic foot lesions. *Clin Infect Dis* 39:S132-S139, 2004 (suppl 2)
- Pecoraro RE, Reiberg GE, Burgess EM: Pathways to diabetic limb amputation. Basis for prevention. *Diabetes Care* 13:513-521, 1990
- Lepantalo M, Biancari F, Tukanen E: Never amputate without consultation of a vascular surgeon. *Diabetes Metab Res Rev* 16: S27-S32, 2000 (suppl 1)
- Norgren L, Hiatt WR, Dormandy JA, et al: Inter-Society Consensus for the Management of Peripheral Arterial Disease (TASC II). *J Vasc Surg* 45:S5-S67 [TASC II]
- Armstrong DG, Lavery LA, Harkless LB: Validation of a diabetic wound classification system: Contribution of depth, infection and vascular disease to the risk of amputation. *Diabetes Care* 21:855-859, 1998
- Hinchliffe RJ, Andros G, Apelqvist J, et al: A systematic review of the effectiveness of revascularization of the ulcerated foot in patients with diabetes and peripheral arterial disease. *Diabetes Metab Res Rev* 28:179-217, 2012 (suppl 1)
- Peregrin JH, Koznar B, Kovac J, et al: PTA of infrapopliteal arteries: Long-term clinical follow-up and analysis of factors influencing clinical outcomes. *Cardiovasc Intervent Radiol* 33:720-725, 2010
- Faglia E, Clerici G, Clerissi J, et al: When is a technically successful peripheral angioplasty effective in preventing above-the-ankle amputation in diabetic patients with critical limb ischemia? *Diabet Med* 24:823-829, 2007
- Ferraresi R, Palena LM, Mauri G, et al: Tips and tricks for a correct "endo approach". *J Cardiovasc Surg* 54:685-711, 2013
- Attinger CE, Evans KK, Bulan E, et al: Angiosomes of the foot and ankle and clinical implications for limb salvage: Reconstruction, incisions, and revascularization. *Plast Reconstr Surg* 117:261S-293S, 2006
- Iida O, Nanto S, Uematsu M, et al: Importance of the angiosome concept for endovascular therapy in patients with critical limb ischemia. *Catheter Cardiovasc Interv* 75:830-836, 2010
- Iida O, Soga Y, Hirano K, et al: Long term results of direct and indirect endovascular revascularization based on the angiosome concept in patients with critical limb ischemia presenting with isolated below-the knee lesions. *J Vasc Surg* 55:363-370, 2012
- Alexandrescu VA, Hubermont G, Philips Y, et al: Selective primary angioplasty following an angiosome model of reperfusion in the treatment of Wagner 1-4 diabetic foot lesions: Practice in a multi-disciplinary diabetic limb service. *J Endovasc Ther* 15:580-593, 2008
- Alexandrescu V, Hubermont G: The challenging topic of diabetic foot revascularization: Does the angiosome-guided angioplasty may improve outcome. *J Cardiovasc Surg* 53:3-12, 2012
- Alexandrescu V, Vincent G, Azdad K, et al: A reliable approach to diabetic neuroischemic foot wounds: Below-the-knee angiosome-oriented angioplasty. *J Endovasc Ther* 18:376-387, 2011
- Alexandrescu V, Söderström M, Venermo M: Angiosome theory: Fact or fiction? *Scand J Surg* 101:125-131, 2012
- Neville RF, Attinger CE, Bulan EJ, et al: Revascularization of a specific angiosome for limb salvage: Does the target artery matter? *Ann Vasc Surg* 23:367-373, 2009
- Varela C, Acín F, de Haro J, et al: The role of foot collateral vessels on ulcer healing and limb salvage after successful endovascular and surgical distal procedures according to an angiosome model. *Vasc Endovasc Surg* 44:654-660, 2010
- Azuma N, Uchida H, Kokubo T, et al: Factors influencing wound healing of critical ischaemic foot after bypass surgery: Is the angiosome important in selecting bypass target artery? *Eur J Vasc Endovasc Surg* 43:322-328, 2012
- Manzi M, Cester G, Palena LM, et al: Vascular imaging of the foot: The first step towards endovascular recanalization. *Radiographics* 31:1623-1636, 2011
- Manzi M, Palena LM, Cester G: Endovascular techniques for limb salvage in diabetics with crural and pedal disease. *J Cardiovasc Surg* 52:485-492, 2011
- Bown MJ, Bolia A, Sutton AJ: Subintimal angioplasty: Meta-analytical evidence of clinical utility. *Eur J Vasc Endovasc Surg* 38:323-337, 2009
- Fusaro M, Dalla Paola L, Biondi-Zoccai G: Pedal-plantar LOOP technique for a challenging below-the-knee chronic total occlusion: A novel approach to percutaneous revascularization in critical lower limb ischemia. *J Invasive Cardiol* 19:34-37, 2007
- Fusaro M, Dalla Paola L, Brigato C, et al: Plantar to dorsalis pedis artery subintimal angioplasty in a patient with critical foot ischemia: A novel technique in the armamentarium of the peripheral interventionist. *J Cardiovasc Med (Hagerstown)* 8:977-980, 2007
- Manzi M, Fusaro M, Ceccacci T, et al: Clinical results of below-the-knee intervention using pedal-plantar loop technique for the revascularization of foot arteries. *J Cardiovasc Surg* 50:331-337, 2009
- Fusaro M, Agostoni P, Biondi-Zoccai G: "Trans-collateral" angioplasty for a challenging chronic total occlusion of the tibial vessels: A novel approach to percutaneous revascularization in critical lower limb ischemia. *Catheter Cardiovasc Interv* 71:268-272, 2008
- Graziani L, Morelli LG: Combined retrograde-antegrade arterial recanalization through collateral vessels: Redefinition of the technique for below-the-knee arteries. *Cardiovasc Intervent Radiol* 34: S78-S82, 2011
- Graziani L, Silvestro A, Monge L, et al: Transluminal angioplasty of peroneal artery branches in diabetics: Initial technical experience. *Cardiovasc Intervent Radiol* 31:49-55, 2008
- Gandini R, Pipitone V, Stefanini M, et al: The "Safari" technique to perform difficult subintimal infragenicular vessels. *Cardiovasc Intervent Radiol* 30:469-473, 2007
- Palena LM, Manzi M: Extreme below-the-knee interventions: Retrograde transmetatarsal or transplantar arch access for foot salvage in challenging cases of critical limb ischemia. *J Endovasc Ther* 19:805-811, 2012
- Palena LM, Brocco E, Manzi M: The clinical utility of below-the-ankle angioplasty using "transmetatarsal artery access" in complex cases of CLI. *Catheter Cardiovasc Interv* 83:123-129, 2014
- Utsunomiya M, Nakamura M, Nakanishi M, et al: Impact of wound blush as an angiographic end point of endovascular therapy for patients with critical limb ischemia. *J Vasc Surg* 55:113-121, 2012