

Clinical outcome of angiosome-oriented infrapopliteal percutaneous transluminal angioplasty for isolated infrapopliteal lesions in patients with critical limb ischemia

Eui-Yong Jeon
Young Kwon Cho
Dae Young Yoon
Dae Jung Kim
Jeong Joo Woo

PURPOSE

We aimed to evaluate the clinical usefulness and outcome of angiosome-oriented percutaneous transluminal angioplasty (IP-PTA) and its clinical outcome for isolated infrapopliteal lesions in diabetic critical limb ischemia.

METHODS

We retrospectively reviewed 70 patients (82 limbs) with diabetic critical limb ischemia who had localized disease at the level of the infrapopliteal artery. Patients underwent IP-PTA between January 2011 and December 2013 and were followed up for a mean of 13 months. The primary target arterial lesions were chosen according to the angiosome concept. We evaluated clinical findings, technical success, and patients' clinical outcome. The angiographic outcome of IP-PTA was assessed using the angiosome score. We analyzed the relationship between the angiosome score and the amputation rate.

RESULTS

There were 69 anterior tibial artery (ATA) lesions, 70 posterior tibial artery (PTA) lesions, and 58 peroneal artery (PA) lesions. The primary target arteries were the ATA (n=43), PTA (n=26), PA (n=2), and ATA + PTA (n=11). We divided the treated limbs into target (n=63) and nontarget (n=19) groups. The overall initial technical success rate was 91.4%. Successful wound healing rates were 87.3% (55/63) and 47.3% (9/19) in the target and nontarget groups, respectively ($P < 0.05$).

CONCLUSION

Angiosome-oriented primary targeted IP-PTA shows a highly effective treatment outcome in diabetic critical limb ischemia. In cases with inadequate angioplastic results of the target artery, IP-PTA of the nontarget artery should be recommended to improve the limb salvage rates.

Diabetic foot is defined as ulceration, infection, and/or destruction of the deep tissues of the foot in diabetic patients, associated with neurologic abnormalities and various degrees of peripheral vascular disease in the lower limb. The relationship between occurrence and healing of diabetic foot and peripheral vascular disease has been well investigated (1). The prevalence of diabetic foot has been reported to be between 2.8% and 10% of the diabetic population (1, 2). In Korea, 1.2% of diabetic patients have diabetic foot disease, and its prevalence has gradually increased to date (3). The risk of major amputation in patients with a diabetic foot ulcer is 8%–29%, and the mortality rate is 39%–80% in patients who have undergone major amputation (4).

Critical limb ischemia is one of the most burdensome problems in the management of diabetic foot, and it is the leading cause of nontraumatic major amputations of the lower limbs. Infrapopliteal percutaneous transluminal angioplasty (IP-PTA) is a safe and effective treatment alternative to bypass surgery for diabetic critical limb ischemia (5). The angiosome concept was introduced by Ian Taylor in 1987 (6), and it has been considered a useful method for selecting the target artery that directly perfuses the diabetic foot wound. Several recent studies have reported that groups with angiosome-oriented target artery recanalization had better wound healing and limb salvage rates compared to groups with IP-PTA without the application of the angiosome concept (7, 8).

The purpose of this study was to evaluate the clinical usefulness of angiosome-oriented IP-PTA and its clinical outcome for pure isolated infrapopliteal lesions in patients with diabetic critical limb ischemia and determine the significant angioplastic factors of IP-PTA that precede more successful treatment outcomes.

From the Department of Radiology (E.Y.J.), Hallym University College of Medicine, Hallym University Sacred Heart Hospital, Anyang, Korea; the Department of Radiology (Y.K.C. ✉ ykchoman@naver.com, D.Y.Y.), Hallym University College of Medicine, Kangdong Seong-Sim Hospital, Seoul, Korea; Department of Radiology (D.J.K., J.J.W.), Eulji University College of Medicine, Eulji General Hospital, Seoul, Korea.

Received 25 March 2015; revision requested 27 April 2015; final revision received 4 June 2015; accepted 26 June 2015.

Published online 6 November 2015.
DOI 10.5152/dir.2015.15129

Methods

Patients

The study protocol was approved by the institutional review board. The requirement for informed consent was waived, because the patients' data were evaluated retrospectively and anonymously.

Between January 2011 and December 2013, we retrospectively reviewed 157 limbs from 135 patients with diabetic foot, which were treated with percutaneous transluminal angioplasty as a first-line treatment for lesions of the infrapopliteal artery. We excluded 54 limbs from 44 patients because of combined vascular lesions in the ipsilateral femoral/popliteal arteries (n=30) and previous treatment with endovascular intervention (n=11) or bypass surgery (n=3). Twenty-one limbs of 21 patients were also excluded due to loss of follow-up over the two-year study period. Therefore, the final study sample consisted of 82 limbs from 70 patients, including 51 men and 19 women (mean age, 69.6 years; range, 43–87 years), who were followed continuously during the study period.

In 70 patients, the presenting symptoms were nonhealing foot wounds of at least two weeks duration (n=70), pre-existing gangrene (n=43), and a nonhealing ulcer (n=27). Among them, 17 patients complained of combined severe resting pain. The patients' characteristics and risk factors are presented in Table 1.

The serologic examination on admission showed the following values: glycated hemoglobin, 8.5±1.9% (4.5%–12.7%); blood

Table 1. Patient characteristics and risk factors

Parameter	No. of patients (n=70)
Men/women, n	51/19
Wound, n	82
Age, mean±SD (years)	69.6±10
Years with diabetes, mean±SD	17.1±9.8
Hypertension, n	63
Chronic renal failure, n	54
End stage renal disease/hemodialysis, n	24
Coronary artery, n	31
Ankle systolic pressure, mean±SD (mmHg)	22.1±11.2
Previous amputation, n	
Major amputation	0
Minor amputation	4
Indication	No. of limbs (n=82)
Wound on single limb/both limbs	58/12
Wagner grade 1–3	29
Wagner grade 4–5	53

urea nitrogen, 24.4±18.8 mg/dL (6.8–117.5 mg/dL); and serum creatinine, 2.7±2.8 mg/dL (0.7–9.9 mg/dL). The mean duration of diabetes was 17.1±9.7 years (range, 1–50 years), and 24 patients were receiving dialysis for end-stage renal disease.

Definitions

Diabetic foot ulcer was defined as a skin defect distal to the calcaneus for at least two weeks (9). We used the Wagner ulcer grading system to classify the foot ulcers (8). The stage above grade 1 (i.e., a partial/full thickness ulcer) was an indication for endovascular recanalization. Healing of the diabetic ulcer was defined as complete epithelialization of the wound tissue (10).

Regarding the level of amputation, minor amputation was defined as an amputation distal to the ankle joint; major amputation was defined as an amputation through or above the ankle joint.

The target artery was defined as an infrapopliteal artery that supplies blood directly to the diabetic foot wound according to the angiosome concept. The nontarget artery was defined as an infrapopliteal artery that can supply blood to the wound indirectly via collaterals.

Critical limb ischemia was defined as persistent, recurring resting pain lasting >2 weeks that requires regular analgesia; an ankle systolic pressure <50 mmHg or an im-

measurable ankle pressure level; and/or ulceration, gangrene, or nonhealing wounds of the foot, which were inclusion criteria for ischemic or neuroischemic ulcers in our study (11). Severity and the extent of the foot ulcers were graded using the Wagner classification on a scale of 1–5 (8).

The limb salvage rate was defined as a survival rate without major amputation around the knee joint during the follow-up period (4). In this study, we evaluated the limb salvage rate during the first 12 months and over the total 24-month study period after the last session of IP-PTA.

Imaging studies

Sixty-six patients underwent lower extremity computed tomography angiography (CTA), and four patients with renal insufficiency underwent Doppler ultrasonography (US) examinations. The mean interval period between the imaging study and IP-PTA was 6.0±11.8 days (range, 0–82 days).

CTA was performed using a Discovery 750 HD 64-channel computed tomography scanner (GE Medical Systems). For all patients, 1.5 mL/kg of a 370 mg/mL iodinated contrast agent (iohexol, Omnipaque, GE Healthcare) was administered at a rate of 3–4 mL/s. Three-dimensional volume-rendered images and maximum intensity projections were reconstructed at a window width of 400 HU and a level of 45 HU.

Main points

- According to the angiosome concept, primary targeted IP-PTA is needed to more effectively treat diabetic critical limb ischemia with high technical success and wound healing rates.
- Successful wound healing rates were 87.3% (55/63) and 47.3% (9/19) in the target and non-target groups, respectively ($P < 0.05$).
- The amputation rate was 33.3% (20/60) in patients with complete success and success, compared with 54.5% (12/22) in patients with partial success and failure ($P > 0.05$).
- In cases with inadequate angioplastic results after primary IP-PTA for target artery, recanalization of the nontarget artery should be recommended to improve the wound healing and limb salvage rates in diabetic critical limb ischemia.

Doppler US was performed using a 5–12 MHz linear probe from a color flow duplex US system iU22 (Philips Medical Systems). One cardiovascular radiologist with more than 10 years of experience in the cardiovascular field performed all the US examinations.

Infrapopliteal percutaneous transluminal angioplasty

All patients were premedicated with aspirin (100 mg/day) and clopidogrel (75 mg/day) at least 72 h before the procedure. All lesions of the localized infrapopliteal arteries were retrospectively analyzed based on preprocedural angiography and CTA. Lesion distribution of the infrapopliteal arteries was recorded and severity of occlusion was categorized as follows: 1) a chronic calcific total occlusion of >10 cm in length; 2) an occlusion at the level of the dorsalis pedis artery, plantar arch, or pedal arch; 3) total occlusion from the ostium; and 4) long segmental severe stenosis of >10 cm in length (degree of stenosis, >70%).

We performed IP-PTA on the primary target lesion, which was decided by the wound location based on the angiosome concept. In cases where recanalization of the target artery failed, an additional IP-PTA was performed on another infrapopliteal artery (i.e., the nontarget artery). If the wounds were multifocal or very extensive, or if all the infrapopliteal arteries were occluded in the involved limbs, IP-PTA was performed for all the infrapopliteal arteries by following a sequence from the target to the nontarget artery based on the angiosome concept as much as possible.

We primarily performed intraluminal guidewire passage; however, the subintimal guidewire passage method was used when the intraluminal guidewire passage failed. We attempted antegrade guidewire passage first and used another guidewire passage method such as transpedal retrograde access when the antegrade guidewire passage failed. We routinely crossed the lesions of the infrapopliteal arteries using a hydrophilic 0.018-inch microguidewire (V18[®], Boston Scientific) or a 0.016-inch microguidewire (Fathom[®], Boston Scientific) in combination with a 2.0–3.0 mm semi-compliant long balloon catheter (>10 cm in balloon length; Savvy Long[®], Cordis Corp.) after inserting a long guiding catheter (Flexor[®] Raabe Guiding Sheath, Cook Inc.). Other endovascular treatments such as stent implantation or intravascular

atherectomy were not performed in any patient. In all cases, the antegrade puncture sites were closed using a hemostatic device (Angio-Seal[®], St. Jude Medical Inc.).

All procedures were performed by two interventional radiologists with more than 15 years of experience in peripheral vascular intervention.

Technical success

The technical success of IP-PTA was based on completion angiography as follows: 1) residual stenosis of <30%; 2) complete recanalization of the lumen and an increased intraluminal flow; 3) highly increased contrast staining or tissue blush around the wound; and 4) an elevated ankle brachial pressure index of >0.6 and a toe pressure of >55 mmHg after IP-PTA (12, 13).

The technical success was separately scored at each level of the infrapopliteal artery and at each level of the involved limbs. According to each level of the infrapopliteal artery, if an artery met all three aforementioned criteria, it received a score of 3 for technical success. If an artery met two of the three criteria, it received a score of 2, and if an artery met one of the three criteria, it received a score of 1.

Angiosome score

According to each level of the involved limb, the technical success was assessed as follows: 1) complete success (3 points), recanalization of both target and nontarget arteries; 2) success (2 points), recanalization of the target artery; 3) partial success (1 point), recanalization of the nontarget artery; and 4) failure (0 points). In this study, the points represented the angiosome score. We correlated the angiosome score and the amputation rate according to each level of the involved limb.

The wound healing rate was estimated between the target and the nontarget groups during the 12-month follow-up period. The target group was defined as successfully performing IP-PTA to the primary target artery with an angiosome score of at least >2 points, and the nontarget group was defined as unsuccessfully performing IP-PTA to the primary target artery with an angiosome score of <1 point or successfully performing IP-PTA to the nonprimary target artery with an angiosome score of >2 points.

Complications

Major and minor complications were defined according to the definitions of the

Society of Interventional Radiology (14). A puncture site hematoma was classified as a minor complication. Pseudoaneurysm at the puncture site, thromboembolism in the distal infrapopliteal artery, and severe bleeding or vascular rupture of the infrapopliteal artery after IP-PTA were classified as major complications that required additional interventional procedure or surgery.

Follow-up

All patients were routinely prescribed oral aspirin (100 mg) and oral clopidogrel (75 mg) once daily for at least three months if there were no contraindications to either drug. The status of the wound was regularly checked and recorded by a referring physician in a medical note until complete wound healing. Indications for repeat IP-PTA during the follow-up included aggravation of the wound. Reocclusion of the recanalized infrapopliteal artery during the follow-up was not included as an indication of repeat IP-PTA, unless there was wound aggravation.

Statistical analysis

We analyzed the relationship between the angiosome score (complete success and success vs. partial success and failure) and the amputation rate using the Pearson chi-square test. Statistical analysis was performed using SPSS 19.0 for Windows (SPSS, IBM Corp.), and a *P*-value <0.05 was considered statistically significant.

Results

In this study, lesions of the infrapopliteal arteries were distributed as follows: 69 anterior tibial artery (ATA) lesions, 70 posterior tibial artery (PTA) lesions, and 58 peroneal artery (PA) lesions (Table 2). Chronic calcific total occlusion of >10 cm in the infrapopliteal arteries was the most common lesion characteristic (63.4%, 125/197), followed by long segmental severe stenosis of >10 cm (20%, 40/197).

The most common wound location was the angiosome territory of the ATA (n=43), followed by the angiosome territory of the PTA (n=26). Eleven limbs had simultaneous wounds in the ATA and PTA territories. The relationship between the ulcer grading system according to the Wegener classification and the angiosome territory is summarized in Table 3.

The baseline ankle systolic pressure prior to IP-PTA was 22.1±11.2 mmHg, which

Table 2. Lesion distribution and severity on preprocedural angiography and lower extremity CTA in patients with diabetic critical limb ischemia

Artery	Chronic calcific total occlusion ^a	Below ankle occlusion	Os occlusion	Long segmental severe stenosis ^a
ATA (n=69)	41	5	8	15
PTA (n=70)	47	3	6	14
PA (n=58)	37	6	4	11
Total (n=197)	125	14	18	40

Data indicate the number of arterial lesions.
 CTA, computed tomography angiography; ATA, anterior tibial artery; PTA, posterior tibial artery; PA, peroneal artery.
^aDefined as occlusion more than 10 cm in length.

Table 3. Wound healing ratios after infrapopliteal percutaneous transluminal angioplasty in target and nontarget arteries

Angiosome	Wegener U/G (No. of involved limbs)	Wound location	Total limbs	WH/TG	WH/NTG
ATA (n=43)	1–3 (16)	Big toe	22	16/18	2/4
	4–5 (27)	Dorsal area	21	15/16	2/5
PTA (n=26)	1–3 (12)	Fore/mid-plantar area	24	15/17	4/7
	4–5 (14)	Heel	2	1/1	0/1
PA (n=2)	1–3 (1)	Lateral heel	2	1/2	0/0
	4–5 (1)				
ATA + PTA (n=11)	1–3 (0)	Multiple	11	7/9	1/2
	4–5 (11)				

Wegener U/G, Wegener ulcer grading; WH, wound healing; TG, target group; NTG, nontarget group; ATA, anterior tibial artery; PTA, posterior tibial artery; PA, peroneal artery.

Table 4. Amputation rates according to treatment success

Outcome (No. of involved limbs)	Amputation (n)		Amputation rate (%)
	Major	Minor	
Complete success (n=26)	0	7	26.9
Success (n=34)	1	12	38.2
Partial success (n=21)	1	11	57.1
Failure (n=1)	0	0	0
Total (n=82)	2	30	39.0

increased to 49.5±13.1 mmHg within one week after IP-PTA (n=66). Four patients were not available to undergo pressure measurements.

A total of 93 sessions of IP-PTA (54 for the ATA, 37 for the PTA, and two for the PA) were performed (Figs. 1, 2). The overall technical success rate was 91.4% (85/93). The ATA had a higher technical success rate (94.4%) than the PTA (86.4%). The most common cause of failure during intraluminal guidewire passage was chronic calcific total occlusion of >10 cm in length at the level of the ATA (n=2) and PTA (n=3) and occlusion at the

level of the dorsalis pedis artery (n=1) and plantar arch (n=2).

We primarily used the intraluminal guidewire passage method in 131 arteries (66.5%), and the subintimal guidewire passage method was used in 66 arteries (33.5%) when the intraluminal guidewire passage failed. There was no case of transpedal retrograde access when the antegrade guidewire passage failed.

Based on the angiosome score, complete success was achieved in 26 limbs (31.7%), success in 34 limbs (41.4%), partial success in 21 limbs (25.6%), and failure in one limb

(1.2%). The number of limbs in the target and nontarget groups were 63 and 19, respectively, and the success wound healing rate was 87.3% (55/63) and 47.3% (9/19) in the target and nontarget groups, respectively ($P < 0.05$). In addition, there was a statistically significant difference in the complete wound healing time between the target and nontarget groups ($P > 0.05$). The overall wound healing ratio was 78.0% during the first 12 months of follow-up (Table 3).

Correlations between the angiosome score and amputation rate are summarized in Table 4. The amputation rate was 33.3% (20/60) in patients with complete success and success, while it was 54.5% (12/22) in patients with partial success and failure. There was no statistically significant difference between the two groups ($P > 0.05$).

There were two minor complications and two major complications in this series. Puncture site hematoma occurred in two cases and was followed up with Doppler US; it spontaneously resolved within one week after IP-PTA. Two cases of arterial perforation and severe bleeding occurred immediately after IP-PTA for lesions of the ATA (data not shown). One case was successfully treated with coil embolization and additional recanalization was performed for the PTA, which was considered the nontarget artery, and it was classified as a partial success based on the angiosome score. The other case was successfully treated with prolonged balloon tamponade. There were no instances of significant distal embolization, pseudoaneurysm at the puncture site, procedure-related death, or 30-day mortality.

During the first 12 months (mean, 13 months; range, 0–25 months) of the follow-up period, amputation was necessary in 32 limbs (39.0%), and two major amputations were performed in the groups with success and partial success (one in each group). The limb salvage rate was 97.5% (80/82) at the 12-month follow-up. Since two major amputations occurred in the target group, the limb salvage rate was 96.8% (61/63) in the target group and was 100% (19/19) in the nontarget group during the 12-month follow-up. During the two-year study period, the overall limb salvage rate was 96.3% (79/82), because additional major amputation was performed in one limb in the group with success 190 days after IP-PTA. In this series, no patients underwent repeat IP-PTA or bypass surgery during the follow-up period. There was no statistical difference in the limb salvage rate between Wagner 1–3 and 4–5 ($P > 0.05$). Four pa-

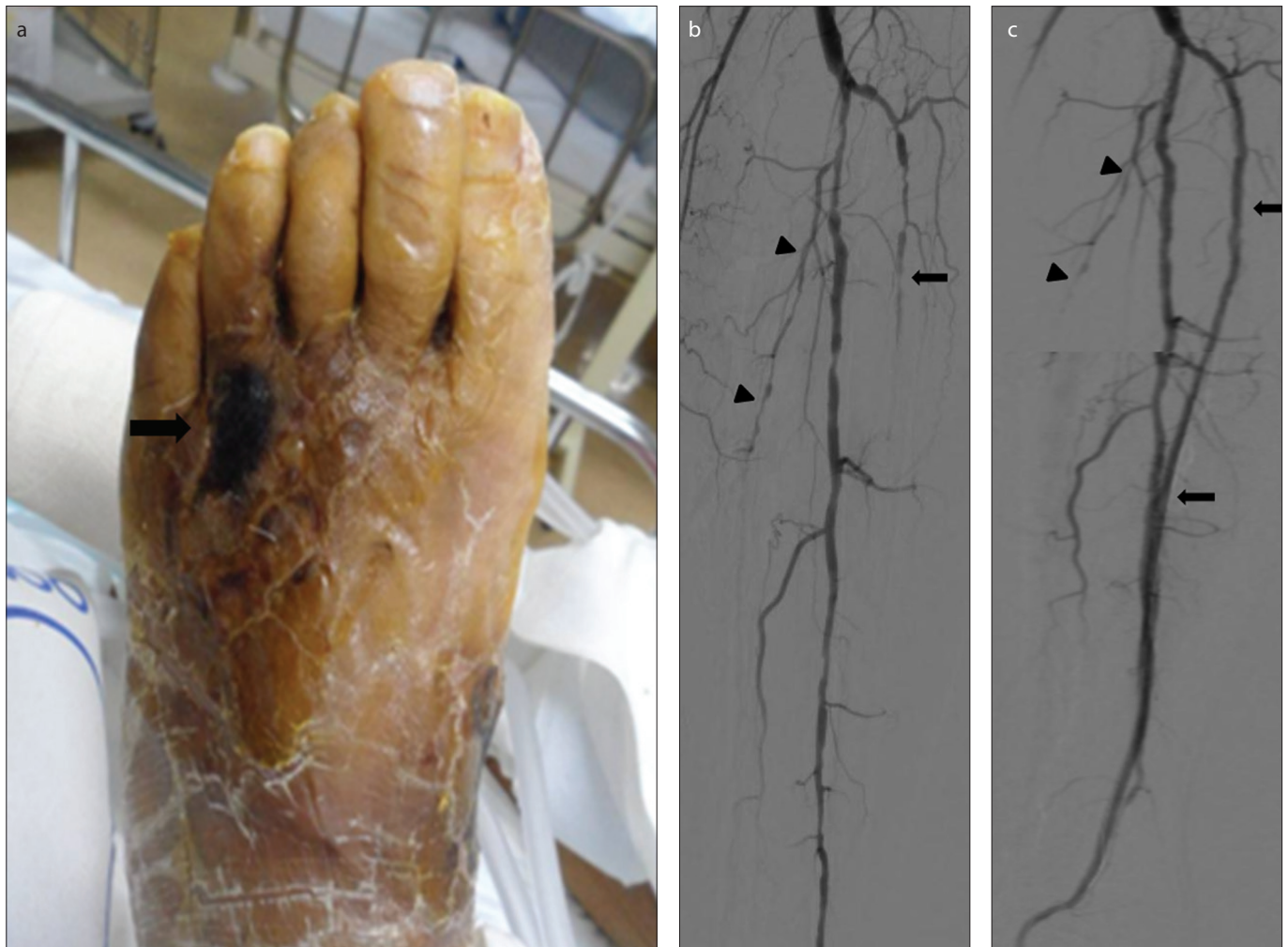

Figure 1. a–c. A 70-year-old female diabetes patient with a nonhealing wound on the dorsum of her left foot. Photograph of the left foot (a) shows a 2×3 cm focal gangrenous wound on the dorsal surface of the left foot (arrow). According to the angiosome concept, the anterior tibial artery is considered the target artery. Initial angiography (b) shows total occlusion of the left anterior tibial artery (arrow), the left posterior tibial artery (arrowheads), and multifocal stenosis of the left peroneal artery. Completion angiography (c) after infrapopliteal percutaneous transluminal angioplasty shows complete recanalization of the left anterior tibial artery (arrows), the left peroneal artery with a normalized luminal diameter, and the non-recanalized state of the left posterior tibial artery (arrowheads), with a technical success score of 3 points. The wound fully recovered within five weeks of angioplasty (not shown).

tients died after complete wound healing during the two-year study period.

Discussion

According to the angiosome concept, primary targeted IP-PTA is needed for more effective treatment in diabetic critical limb ischemia, as it has higher technical success and wound healing rates. In this study, successful wound healing rates were 87.3% (55/63) and 47.3% (9/19) in the target and nontarget groups, respectively ($P < 0.05$). However, the amputation rate was not significantly different between patients with complete success and success (33.3%, 20/60) compared to those with partial success and failure (54.4%, 12/22) ($P > 0.05$).

Diabetic foot is one of the most devastating complications in patients with diabetes.

Diabetic foot ulcers result from simultaneous action of multiple contributing causes, including peripheral vascular disease, neuropathy, trauma, and infection. Poor circulation resulting from peripheral vascular disease is the leading cause of diabetic ulcers and is an important factor that impairs the ulcer healing process (15).

Many previous studies showed that improved blood flow from endovascular treatment facilitates wound healing, pain relief, and patient satisfaction (16, 17). In a recent cohort study on 1,023 patients, Söderström et al. (16) compared the effectiveness of endovascular and surgical recanalization for chronic severe diabetic critical limb ischemia. They reported the limb salvage rate, survival rate, and amputation-free survival rate as 75.3%, 47.5%, and 37.7%, respectively, at five-year follow-up after endovascular

recanalization; these findings were similar to those of surgical recanalization. Currently, endovascular recanalization, which is less invasive, has been considered as a primary treatment modality in patients with diabetic critical limb ischemia, especially in those with less than two years of life expectancy, poor general condition, and serious systemic risk factors (18).

The angiosome concept divides the foot into anatomic units supplied by specific source arteries. According to this concept, the foot can be divided into five perfusion territories (angiosomes) supplied by three arteries (the ATA, PTA, and PA) that originate from the main popliteal artery and adjacent angiosomes connected by collateral vessels (6, 19). This strategy is particularly important for vascular interventional radiologists when planning endovascular treatment for

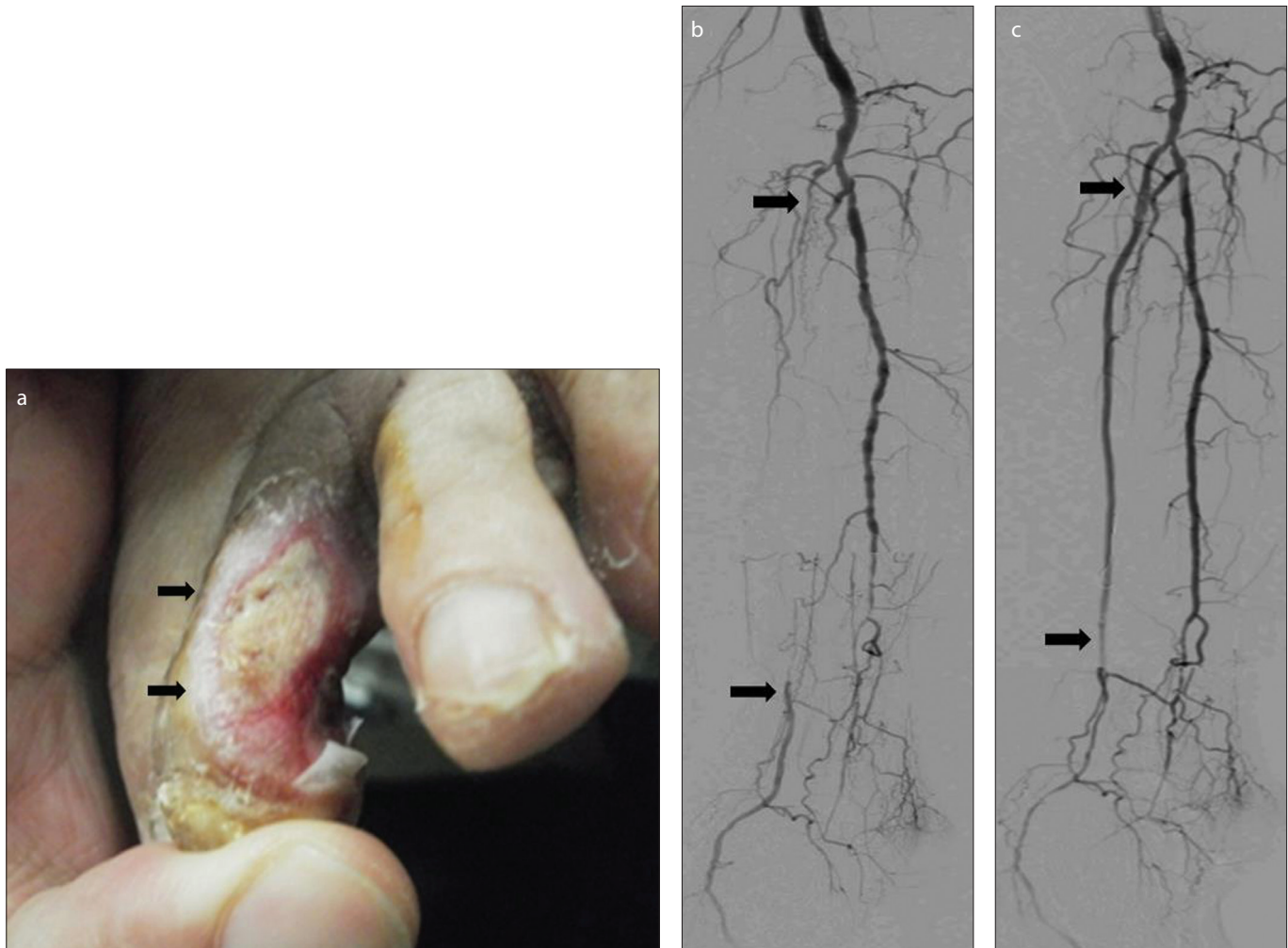


Figure 2. a–c. A 72-year-old male diabetes patient with a nonhealing wound on the lateral surface of left second toe. Photograph of the second toe on the left foot (a) shows a 2×2 cm chronic nonhealing ulcer on the lateral surface (arrows). According to the angiosome concept, the posterior tibial artery is considered the target artery in this case. Initial angiography (b) shows total occlusion of the right anterior tibial artery, the right posterior tibial artery (arrows), and distal segmental occlusion of the right peroneal artery. Completion angiography (c) after infrapopliteal percutaneous transluminal angioplasty shows a completely recanalized right posterior tibial artery (arrows), with a technical success score of 3 points. The wound fully recovered within six weeks of angioplasty (not shown).

diabetic critical limb ischemia, because it allows for the specific selection of the target artery that directly supplies blood flow to the wound. Direct recanalization of the target artery significantly affects effective wound healing and the limb salvage rate in diabetic foot compared to indirect revascularization (20, 21). In this study according to the angiosome concept, the most common site of diabetic foot wounds was the first toe supplied by the ATA, and the least common site was the lateral heel supplied by the PA, which is similar to the previous study.

With development of the angiosome concept and continuous advances in endovascular treatment, recent studies on IP-PTA for critical limb ischemia have reported technical success rates of up to 90%, a one-year arterial patency rate of 40%–70%, and a one-

year limb salvage rate of 90%–95% (16, 22).

In Korea, Bae et al. (23) analyzed 205 cases of endovascular recanalization for chronic severe critical limb ischemia and reported a technical success rate of 85%, major amputation rate of 2%, one-year limb salvage rate of 94.8%, and three-year limb salvage rate of 92.0%. Their limb salvage rate was >90% after appropriate IP-PTA, which emphasizes the importance of recanalization of at least one infrapopliteal artery that supplies blood directly to the lesion.

In our study, the limb salvage rates during the first 12-month follow-up period and the total 24-month study period were 97.5% and 96.3%, respectively, which were slightly higher than those of previous studies (18). The wound healing rate of the target group was significantly higher than that

in the nontarget group; however, the amputation rate of the group with complete success and success compared with that of the group with partial success and failure did not reach statistical significance, which is similar to other recent studies (16, 24).

Two patients underwent major amputations during the first 12-month follow-up period after IP-PTA, despite a relatively successful angiosome score. This poor result seems likely to be influenced by other risk factors such as severe infection and extensive wound distribution before IP-PTA and an insufficient period of wound healing after IP-PTA.

We acknowledge several limitations of this study. First, our retrospective design has potential selection bias that may affect our results in terms of evaluating the early

state of wounds and analyzing the degree of improvement in the lesions. Second, the number of patients was small, patients were collected from a single institution, and the follow-up period was relatively short, which may affect the generalizability of our results.

In conclusion, angiosome-oriented primary targeted IP-PTA provides a highly effective treatment outcome in diabetic critical limb ischemia. In cases with inadequate angioplastic results of the target artery, IP-PTA of the nontarget artery should be attempted to improve the limb salvage rates.

Conflict of interest disclosure

The authors declared no conflicts of interest.

References

1. Setacci C, de Donato G, Setacci F, Chisci E. Diabetic patients: epidemiology and global impact. *J Cardiovasc Surg* 2009; 50:263–273.
2. Wild S, Roglic G, Green A, Sicree R, King H. Global prevalence of diabetes: estimates for the year 2000 and projections for 2030. *Diabetes Care* 2004; 27:1047–1053. [\[CrossRef\]](#)
3. Kim TS, Kang JW, Lee SJ, Huh YJ, Kim HJ. Clinical analysis and results after the amputations of lower extremities due to diabetic foot. *J Korean Foot Ankle Soc* 2009; 13:50–54.
4. Moulik PK, Mtonga R, Gill GV. Amputation and mortality in new-onset diabetic foot ulcers stratified by etiology. *Diabetes Care* 2003; 26:491–494. [\[CrossRef\]](#)
5. Zhan LX, Bharara M, White M, et al. Comparison of initial hemodynamic response after endovascular therapy and open surgical bypass in patients with diabetes mellitus and critical limb ischemia. *J Vasc Surg* 2012; 56:380–386. [\[CrossRef\]](#)
6. Taylor GI, Pan WR. Angiosomes of the leg: anatomic study and clinical implications. *Plast Reconstr Surg* 1998; 102:599–616. [\[CrossRef\]](#)
7. Alexandrescu V, Vincent G, Azdad K, et al. A reliable approach to diabetic neuroischemic foot wounds: below-the-knee angiosome-oriented angioplasty. *J Endovasc Ther* 2011; 18:376–387. [\[CrossRef\]](#)
8. Graziani L, Silvestro A, Bertone V, et al. Vascular involvement in diabetic subjects with ischemic foot ulcer: a new morphologic categorization of disease severity. *Eur J Vasc Endovasc Surg* 2007; 33:453–460. [\[CrossRef\]](#)
9. Setacci C, De Donato G, Setacci F, Chisci E. Ischemic foot: definition, etiology and angiosome concept. *J Cardiovasc Surg* 2010; 51:223–231.
10. Azuma N, Uchida H, Kokubo T, Koya A, Akasaka N, Sasajima T. Factors influencing wound healing of critical ischaemic foot after bypass surgery: is the angiosome important in selecting bypass target artery? *Eur J Vasc Endovasc Surg* 2012; 43:322–328. [\[CrossRef\]](#)
11. Williams DT, Price P, Harding KG. The influence of diabetes and lower limb arterial disease on cutaneous foot perfusion. *J Vasc Surg* 2006; 44:770–775. [\[CrossRef\]](#)
12. Utsunomiya M, Nakamura M, Nakanishi M, et al. Impact of wound blush as an angiographic end point of endovascular therapy for patients with critical limb ischemia. *J Vasc Surg* 2012; 55:113–121. [\[CrossRef\]](#)
13. Wütschert R, Bounameaux H. Predicting healing of arterial leg ulcers by means of segmental systolic pressure measurements. *Vasa* 1998; 27:224–228.
14. Sacks D, Marinelli DL, Martin LG, Spies JB; Society of Interventional Radiology Technology Assessment Committee. Reporting standards for clinical evaluation of new peripheral arterial revascularization devices. *J Vasc Interv Radiol* 2003; 14:395–404. [\[CrossRef\]](#)
15. Medina A, Scott PG, Ghahary A, Tredget EE. Pathophysiology of chronic nonhealing wounds. *J Burn Care Rehabil* 2005; 26:306–319. [\[CrossRef\]](#)
16. Söderström M, Albäck A, Biancari F, Lappalainen K, Lepäntalo M, Venermo M. Angiosome-targeted infrapopliteal endovascular revascularization for treatment of diabetic foot ulcers. *J Vasc Surg* 2013; 57:427–435. [\[CrossRef\]](#)
17. Ferraresi R, Centola M, Ferlini M, et al. Long-term outcomes after angioplasty of isolated, below-the-knee arteries in diabetic patients with critical limb ischaemia. *Eur J Vasc Endovasc Surg* 2009; 37:336–342. [\[CrossRef\]](#)
18. Setacci C, de Donato G, Teraa M, et al. Chapter IV: Treatment of critical limb ischemia. *Eur J Vasc Endovasc Surg* 2011; 42:43–59. [\[CrossRef\]](#)
19. Manzi M, Cester G, Palena LM, Alek J, Candeo A, Ferraresi R. Vascular imaging of the foot: the first step toward endovascular recanalization. *Radiographics* 2011; 31:1623–1636. [\[CrossRef\]](#)
20. Biancari F, Juvonen T. Angiosome-targeted lower limb revascularization for ischemic foot wounds: systematic review and meta-analysis. *Eur J Vasc Endovasc Surg* 2014; 47:517–522. [\[CrossRef\]](#)
21. Alexandrescu V, Söderström M, Venermo M. Angiosome theory: fact or fiction? *Scand J Surg* 2012; 101:125–131. [\[CrossRef\]](#)
22. Odink H, van den Berg A, Winkens B. Technical and clinical long-term results of infrapopliteal percutaneous transluminal angioplasty for critical limb ischemia. *J Vasc Interv Radiol* 2012; 23:461–467. [\[CrossRef\]](#)
23. Bae JI, Won JH, Han SH, et al. Endovascular revascularization for patients with critical limb ischemia: impact on wound healing and long term clinical results in 189 limbs. *Korean J Radiol* 2013; 14:430–438. [\[CrossRef\]](#)
24. Kabra A, Suresh KR, Vivekanand V, Vishnu M, Sumanth R, Nekkanti M. Outcomes of angiosome and non-angiosome targeted revascularization in critical lower limb ischemia. *J Vasc Surg* 2013; 57:44–49. [\[CrossRef\]](#)